

Long-term outcomes of pectoralis major transfer for scapular winging due to long thoracic nerve palsy results after a median follow-up of 17 years

Geurkink, Timon H.; Marang-van de Mheen, Perla J.; Robbers, Tim; Nagels, Jochem; Nelissen, Rob G.H.H.

DOI

[10.1016/j.jseint.2024.04.002](https://doi.org/10.1016/j.jseint.2024.04.002)

Publication date

2024

Document Version

Final published version

Published in

JSES International

Citation (APA)

Geurkink, T. H., Marang-van de Mheen, P. J., Robbers, T., Nagels, J., & Nelissen, R. G. H. H. (2024). Long-term outcomes of pectoralis major transfer for scapular winging due to long thoracic nerve palsy: results after a median follow-up of 17 years. *JSES International*, 8(4), 822-827. <https://doi.org/10.1016/j.jseint.2024.04.002>

Important note

To cite this publication, please use the final published version (if applicable). Please check the document version above.

Copyright

Other than for strictly personal use, it is not permitted to download, forward or distribute the text or part of it, without the consent of the author(s) and/or copyright holder(s), unless the work is under an open content license such as Creative Commons.

Takedown policy

Please contact us and provide details if you believe this document breaches copyrights. We will remove access to the work immediately and investigate your claim.



ELSEVIER

Contents lists available at ScienceDirect

JSES International

journal homepage: www.jsesinternational.org

Long-term outcomes of pectoralis major transfer for scapular winging due to long thoracic nerve palsy: results after a median follow-up of 17 years



Timon H. Geurkink, MD^{a,*}, Perla J. Marang-van de Mheen, PhD^{a,b}, Tim Robbers, MD^a, Jochem Nagels, MD^a, Rob G.H.H. Nelissen, MD, PhD^a

^aDepartment of Orthopaedics, Leiden University Medical Centre, Leiden, the Netherlands

^bSafety & Security Science and Centre for Safety in Healthcare, Delft University of Technology, Delft, The Netherlands

ARTICLE INFO

Keywords:

Scapular winging
Scapula alata
Serratus anterior muscle
Long thoracic nerve
Pectoralis major tendon transfer
Shoulder
Surgery

Level of evidence: Level IV; Case Series;
Treatment Study

Background: A pectoralis major (PM) transfer is a viable treatment option for patients with scapular winging due to long thoracic nerve (LTN) palsy not responding to nonsurgical management. However, the long-term outcomes remain unknown. Therefore, the purpose of this study was to evaluate the long-term outcome of shoulder function (ie, minimum follow-up of 10 years) and quality-of-life (QoL) of patients treated for scapular winging due to LTN palsy with a PM transfer.

Methods: This observational cohort study included 15 patients (16 shoulders) who underwent PM transfer, using a tendoachilles allograft, between 1995 and 2012. Shoulder forward flexion and abduction were analyzed preoperatively, 1 year after surgery and at the final follow-up. SF-36 component scores (physical component summary (PCS) and mental component summary (MCS)) were used to evaluate the QoL.

Results: Shoulder forward flexion and abduction measured in degrees improved from 86 (SD 14.5) and 82 (SD 33.8) preoperatively to 140 (SD 27.3) and 138 (31.3) at 1 year postoperatively. After a median follow-up of 17 years, mean shoulder functions were slightly lower than at 1 year postoperatively, but still better than preoperative function, ie, forward flexion 121 (SD 41.9) and abduction 122 (SD 44.5). The mean PCS score at the final follow-up was 41.9 (SD 9.7), and the mean MCS score was 49.9 (SD 12.5). Better shoulder function at the final follow-up was significantly associated with higher QoL in terms of PCS scores ($P = .023$), but not MCS scores ($P = .287$).

Conclusion: The results of the present study indicate that PM transfer augmented with an achilles tendon allograft for scapular winging due to LTN palsy leads to functional improvements that persist in long term. These functional improvements likely translate to better QoL based on their association.

© 2024 The Author(s). Published by Elsevier Inc. on behalf of American Shoulder and Elbow Surgeons. This is an open access article under the CC BY-NC-ND license (<http://creativecommons.org/licenses/by-nc-nd/4.0/>).

Scapular winging is a rare condition of the shoulder girdle, characterized by the abnormal protrusion of the scapula relative to the thorax during forward flexion of the arm.¹² This abnormal

scapular movement pattern frequently results from long thoracic nerve (LTN) palsy, resulting in weakness of the serratus anterior (SA) muscle with subsequent inability to stabilize the scapula to the thorax during shoulder motion.^{3,16,24,25} In clinical practice, patients report limited forward flexion due to the inability to fixate the scapula against the thorax, with subsequent overuse or overcompensation of other shoulder girdle muscles, resulting in more rapid muscle fatigue and pain.^{3,5,17,22}

The majority of patients with scapular winging due to LTN palsy have complete functional recovery within two years with nonsurgical management.¹⁹ Therefore, patients with LTN palsy should be treated nonsurgically (eg, prevention of overuse, physical therapy) for at least this period.⁹ In case of insufficient functional recovery at 2 years, surgical intervention through a pectoralis major (PM) tendon transfer can be considered. PM transfer surgery aims to restore scapulothoracic stabilization by transferring the PM muscle

Approval for this study was sought from the Medical Ethical Committee Leiden (CME Leiden, code 058) and deemed exempt under Dutch law (reference number G20.123). All participants gave their consent to participate.

This work was performed at the Leiden University Medical Center (LUMC), Leiden, the Netherlands.

Ethical board approval was not deemed necessary by the local medical ethical research committee (G20.123) due to the nature of the research and its minimal risk to participants.

*Corresponding author: Timon H. Geurkink, MD, Department of Orthopedic Surgery, Leiden University Medical Center, J11-R70, P.O. Box 9600, Leiden 2300 RC, the Netherlands.

E-mail address: t.h.geurkink@lumc.nl (T.H. Geurkink).

<https://doi.org/10.1016/j.jseint.2024.04.002>

2666-6383/© 2024 The Author(s). Published by Elsevier Inc. on behalf of American Shoulder and Elbow Surgeons. This is an open access article under the CC BY-NC-ND license (<http://creativecommons.org/licenses/by-nc-nd/4.0/>).

to the scapula as a substitute for the loss in SA muscle function, thereby restoring shoulder function.²⁸

A recent systematic review with a mean follow-up of three years showed that patients with scapular winging due to LTN palsy significantly improved in function and pain after a PM transfer.⁸ These short-term outcomes indicate that a PM transfer is a viable option for patients not responding to nonsurgical management. However, data on long-term outcomes and their impact on quality-of-life (QoL) are lacking, even though this is important information for patient counselling and expectation management. The present study aimed to report the long-term improvement in shoulder function, ie, range of motion (after a minimum follow-up of 10 years) after PM transfer in patients with scapular winging due to LTN palsy and gauge the impact on QoL by examining the association of QoL with function measures.

Materials and methods

Study design and participants

This was a retrospective cohort study of all consecutive patients with scapular winging due to LTN palsy who underwent PM transfer surgery at the department of Orthopaedics at Leiden University Medical Center (LUMC, The Netherlands) between January 1995 and December 2012 to ensure a minimal follow-up duration of ten years. Ethical board approval was not deemed necessary by the local medical ethical research committee (G20.123) due to the

nature of the research and its minimal risk to participants. All patients over 18 years of age who underwent PM transfer for LTN palsy proven by electromyography (EMG) were eligible for inclusion. The senior author (RN) initially diagnosed the condition through clinical examination, involving visual inspection for winging during forward flexion or while pushing against a wall in a push-up position. The diagnosis was subsequently confirmed by EMG. The exclusion criteria were previous surgery to the affected shoulder, language barrier, and lack of informed consent.

Out of 17 eligible patients (18 shoulders, 1 patient had bilateral pathology), in total 16 patients (17 shoulders) were included in the study (Fig. 1). All of these patients had limited range of motion (ROM) of the affected shoulder joint and had no recovery after non-surgical management (ie, physical therapy aimed at restoring shoulder function) for more than 24 months. All surgeries were performed by a single surgeon (RN). 1 Patient was lost to follow-up due to death, leaving 15 patients (16 shoulders) available for analysis (Fig. 1).

Surgical procedure

During surgery, patients were positioned in a semi-lateral decubital position. Surgical exposure was performed by an anterior (deltopectoral) approach, and a posterior approach to the angulus inferior of the scapula. Through the deltopectoral approach, the three parts of the PM muscle were identified: the clavicular, the sternocostal and the abdominal part. The sternocostal part was

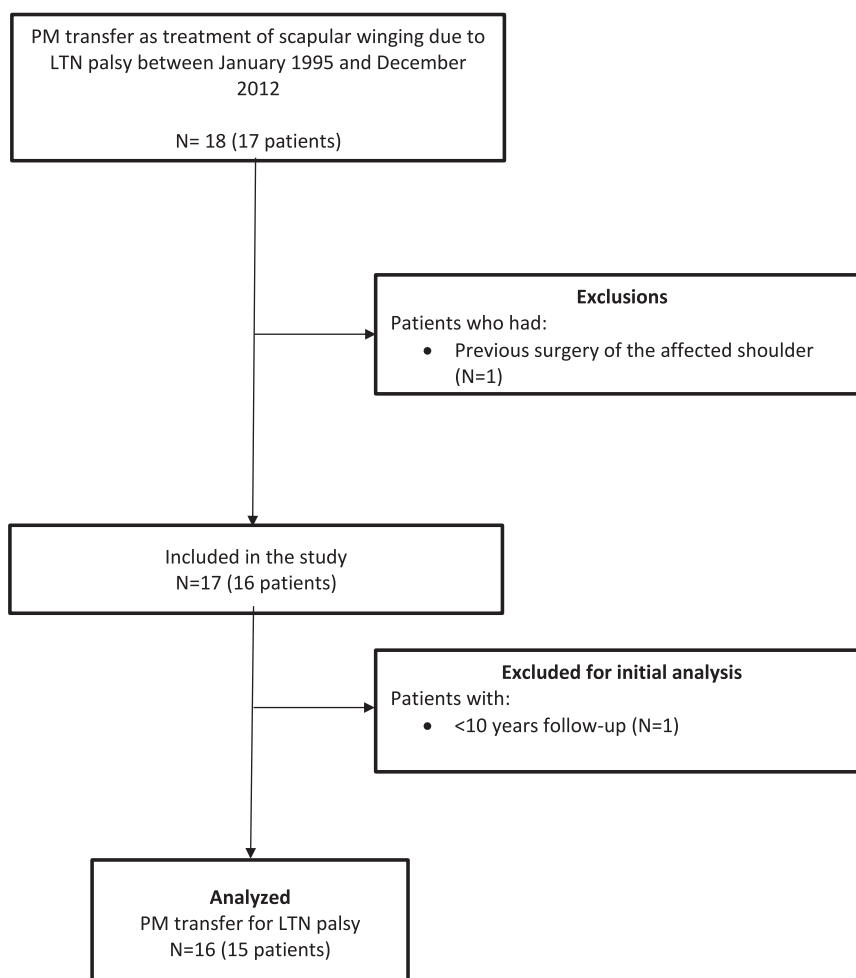


Figure 1 Flow chart of study selection. PM, Pectoralis major; LTN, Long Thoracic Nerve; N, number of shoulders.

released from the humerus, carefully identifying the pectoral nerves in the interval between the clavicular and sternocostal parts. Then the second incision was made at the level of the angulus inferior (about 4–5 cm long). A muscle split was done of the latissimus dorsi overlaying the angulus inferior of the scapula, identifying the bony lateral edge of the angulus inferior of the scapula, subperiosteal stripping of the atrophied SA muscle and proximal part of the subscapular muscle with cautery, exposing the bony part of the angulus inferior. A 6 mm drill hole was made, which is slightly enlarged with a bone nibbler to accommodate the tunneling of the achilles tendon allograft. The allograft was first weaved with its wide proximal part around the the sternocostal part of the PM, such to create a tube of pectoral muscle and allograft. Next, a tunnel was made from the deltopectoral window to the posterior thorax to the level of the angulus inferior. The sternocostal PM-allograft construct was passed from anterior to posterior to the angulus inferior of the scapula. This construct was pulled from ventral to dorsal through the bony hole, with the long sutures back to the deltopectoral surgical wound, thus tensioning the pectoral muscle fixation to the scapula. The allograft was fixed onto itself using non-resorbable sutures just proximal from the bony hole in the scapula.

Data collection and outcome measures

Individual patient records were independently evaluated by two of the authors (TG and TR) to extract patient demographics at the time of surgery and clinical data (ie, ROM of the shoulder) both preoperatively and one year after surgery. All patients were contacted by e-mail or telephone and invited to return for long-term (final) follow-up examinations of their shoulder function at the Laboratory for Kinematics and Neuromechanics (LUMC, the Netherlands) between January and July 2022. Two independent researchers (TG and TR), who were not involved in their surgery, conducted a comprehensive assessment of long-term outcomes through the following measurements: shoulder ROM (ie, shoulder forward flexion and abduction measured in degrees), VAS scores for pain (VAS no pain: 0), constant shoulder (CS) score, Disability of the Arm, Shoulder and Hand questionnaire, the SF-36 Health Survey Questionnaire to assess the health-related QoL.

Statistical analysis

Data were described using descriptive statistics, using means, standard deviation (SD), and 95% confidence intervals (CI) for parametric data and medians and interquartile range (IQR) for non-parametric data, unless stated otherwise. Numbers and percentages were used for categorical data. Shoulder function (ie, active ROM) over time (preoperatively, 1 year after surgery and at the final follow-up) was analyzed using repeated-measures ANOVA to measure within-subject effects. Summary scores of the SF-36 (mental component summary (MCS) and physical component summary (PCS)) were calculated by standardizing the SF-36 scores against Dutch population means, standard deviations, and factor coefficients (ie, a MCS and PCS score of 50 corresponds to the mean score for the general Dutch population).²⁷ SF-36 scores from our study were compared with US and Dutch population norm data and with the mean scores of five other common shoulder pathologies (ie, anterior glenohumeral instability, complete reparable rotator cuff tear, adhesive capsulitis, glenohumeral osteoarthritis, and impingement syndrome).^{1,7} The association between the QoL summary scores (ie, MCS and PCS) and shoulder function (ie, active shoulder forward flexion at the last follow-up) at the final follow-up was analyzed with linear regression analysis. All statistical analyses were performed using the statistical package SPSS version 25.0 (IBM, Armonk, NY, USA).

Results

Patients had a median age of 33 years (range 18–50) at the time of surgery, and ten (63%) were female. Six patients had a traumatic origin of their LTN palsy, the cause was idiopathic in five patients (including the patient with bilateral winging), and four were iatrogenic (ie, mastectomy, axillary dissection, first rib resection (2)). The dominant arm was affected in nine (56%) patients. The median time to final follow-up was 17 years (range 10–25).

At the final follow-up, patients reported a median VAS pain score of 2.0 (IQR 0.7–5.4) at rest and 2.9 (IQR 1.1–5.9) during movement. The median constant score of the affected arm was 68 (IQR 42–91) compared with 89 (IQR 80–97) of the unaffected arm. The median Disability of the Arm, Shoulder and Hand questionnaire score was 30 (IQR 15–38). Residual scapular winging was observed in five patients (33%) at the final follow-up. Twelve patients (80%) would recommend the surgical procedure to friends, and all patients were happy with the cosmesis. No postoperative (postop) complications were reported. None of the patients underwent any other shoulder surgery following the PM transfer.

Functional outcome scores of individual patients are presented in Table I. Forward flexion improved from 86 (SD 14.5) preoperatively to 140 (SD 27.3) at 1 year postoperatively, while abduction increased from 82 (SD 33.8) to 138 (31.3), respectively (Fig. 2). After a median follow-up of 17 years, mean shoulder functions were slightly lower than at 1 year, but still better compared to preoperative (preop) function, ie, forward flexion 121 (SD 41.9) and abduction 122 (SD 44.5), respectively (Fig. 2). For both shoulder forward flexion and abduction, repeated-measures ANOVA showed a significant effect of treatment over time ($P < .001$). Three patients (patients 5, 6, and 14 in Table I) had deterioration of their good 1-year postop result at the final follow-up, which was even worse than preopforward flexion.

SF-36 scores at the final follow-up are shown in Table II. The role-physical domain score was the lowest (mean: 48.4; SD 41.3) and the mental health domain had the highest score (mean 78.5; SD 17.5). The mean PCS score (41.9; SD 9.7) was considerably lower than US and Dutch general population norm data, but higher than the mean PCS scores of other common shoulder pathologies (Table II). The mean MCS score (49.9; SD 12.5) was comparable to general population means and MCS scores of other shoulder pathologies. Better shoulder forward flexion function at the final follow-up was significantly associated with higher QoL in terms of PCS scores (Beta = 0.131, $P = .023$), but not MCS scores (Beta = 0.085, $P = .287$).

Discussion

This is the first study to describe long-term improvement in shoulder function in a cohort of patients with LTN palsy treated with PM transfer. Results of the present study demonstrate that the shoulder function of patients with scapular winging due to LTN palsy that were unresponsive to nonsurgical management substantially improved after PM transfer and that the functional improvements were still present in the majority of patients after a median follow-up of 17 years. These functional improvements likely translate into improvements in QoL as better shoulder function was associated with better PCS scores. Another new finding of this study is that, despite significant improvements in shoulder function after PM transfer, scapular winging still impacts the long-term QoL. On average, lower QoL was observed in our cohort than for the general Dutch population, indicating that these patients still experience greater limitations in physical functions

Table 1
Functional outcome scores of individual patients.

Patient	Age at time of surgery (y)	Follow-up time (y)	Forward flexion			Abduction			Residual winging at the final follow-up
			Preoperative	1 year	Last follow-up	Preoperative	1 year	Last follow-up	
1	31	16	70	160	170	110	160	170	No
2	37	25	100	180	180	90	180	180	No
3	26	24	80	110	100	75	125	100	Yes
4	40	22	90	160	130	100	170	170	Yes
5*	18	22	90	160	80	60	160	90	No
6	26	20	70	105	50	50	100	40	Yes
7	35	19	50	150	60	60	130	90	Yes
8	23	20	90	170	150	60	170	130	No
9*	22	18	80	100	100	60	100	100	No
10	26	10	95	100	100	60	80	80	Yes
11	38	16	100	140	140	110	130	140	No
12	50	14	70	130	160	60	150	160	No
13	21	14	95	140	120	50	140	130	No
14	46	13	90	120	70	70	100	50	No
15	34	13	100	170	170	170	170	170	No
16	38	12	100	140	150	130	130	150	No
Mean (SD)			86 (14.5)	140 (27.3)	121 (41.9)	82 (33.8)	138 (31.3)	122 (44.5)	

SD, standard deviation.

*Patient with bilateral winging.

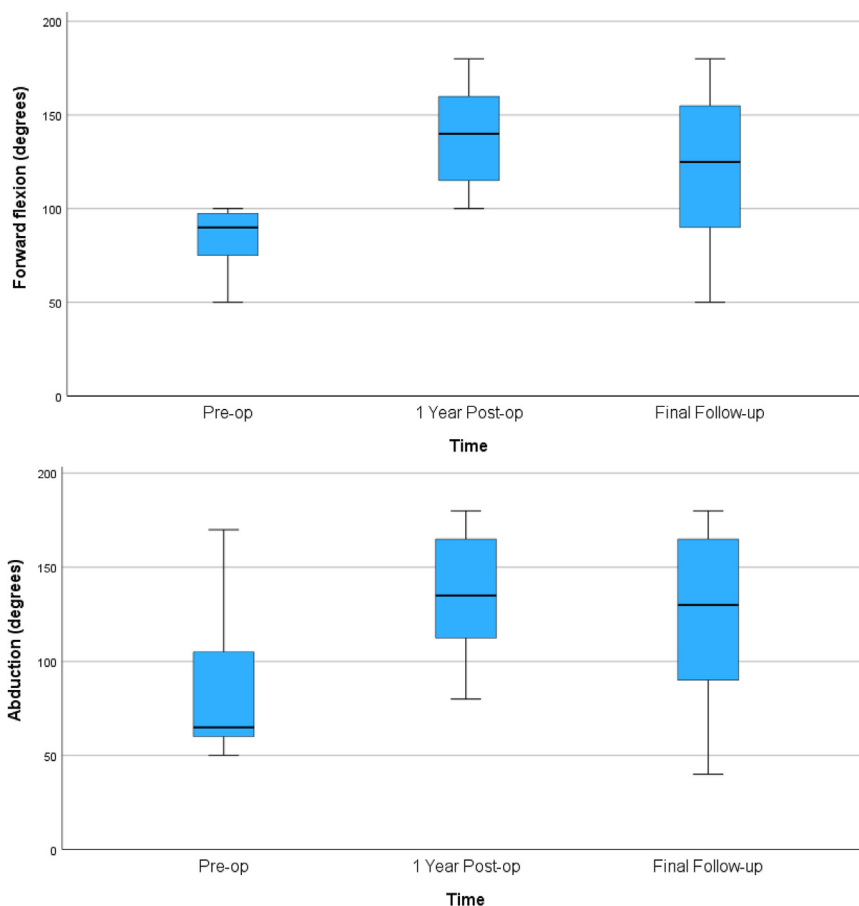


Figure 2 Boxplots showing shoulder function before and after PM transfer for LTN palsy. Boxplots showing shoulder ranges of motion (ie, forward flexion and abduction) before and after PM transfer for LTN palsy. Boundaries of the boxplots indicate the 25th and 75th percentile. Whiskers below and above indicate the minimum and maximum of the variables. The median is indicated with the black line. *Preop*, Preoperative; *Postop*, Postoperative; *PM*, pectoralis major; *LTN*, long thoracic nerve.

and role participation, but scores in the mental domain did not differ.

A PM transfer to compensate for the loss of SA function caused by LTN palsy was first described by Tubby in 1904.²⁶

Since then, several studies have described different surgical techniques for attaching the PM either directly to the scapula or after augmenting and lengthening with various allografts or autografts. Studies using an augmented and lengthened tendon

Table II
SF-36 scores from the present study in comparison to US- and Dutch general population norms and five common shoulder pathologies.

Scales/Summaries	US general population norms (SD)	Dutch general population norms (SD)	Anterior glenohumeral instability (SD)	Complete reparable rotator cuff tear (SD)	Adhesive capsulitis (SD)	Glenohumeral osteoarthritis (SD)	Impingement syndrome (SD)	Scapular winging (after PM transfer) (SD)
Physical functioning	84.2 (23.3)	83.0 (22.8)	71.3 (21.6)	56.9 (25.8)	67.2 (22.4)	57.5 (33.6)	62.9 (23.2)	68.7 (22.5)
Role-physical	81.0 (34.0)	76.4 (36.3)	24.7 (36.4)	26.8 (39.3)	34.5 (37.0)	41.0 (45.4)	29.8 (38.1)	48.4 (41.3)
Bodily pain	75.2 (23.7)	74.9 (23.4)	36.8 (22.8)	29.9 (19.3)	37.6 (20.6)	36.6 (22.7)	35.0 (16.5)	63.9 (30.0)
General health	72.0 (20.3)	70.7 (20.7)	72.0 (20.6)	67.9 (24.7)	70.2 (25.1)	71.7 (20.2)	70.4 (21.2)	62.2 (20.7)
Vitality	60.9 (21.0)	68.6 (19.3)	55.4 (21.7)	50.2 (22.2)	52.1 (24.1)	58.5 (23.8)	55.8 (23.6)	60.3 (23.9)
Social functioning	83.3 (22.7)	84.0 (22.4)	62.2 (28.5)	57.1 (31.9)	74.1 (29.2)	72.9 (33.8)	65.0 (26.9)	70.3 (30.6)
Role-emotional	81.3 (33.0)	82.3 (32.9)	66.2 (43.2)	58.8 (44.5)	70.9 (42.1)	69.6 (42.9)	62.6 (43.6)	60.4 (47.5)
Mental health	74.7 (18.1)	76.8 (17.4)	68.2 (19.3)	67.2 (22.1)	72.7 (21.8)	73 (20.1)	70.1 (21.5)	78.5 (17.5)
Physical component summary	50.0	50.0	38.2 (9.0)	34.7 (9.2)	37.6 (8.8)	36.4 (11.8)	36.6 (8.3)	41.9 (9.7)
Mental component summary	50.0	50.0	48.1 (21.2)	47.2 (12.6)	51.0 (12.6)	52.2 (11.4)	49.1 (12.6)	49.9 (12.5)

SD, standard deviation; PM, pectoralis major.

graft most commonly used a fascia lata autograft.^{3,10,16,17,20,23} The use of a graft provides the ability to control the length of the PM and lessen the risk of putting too much stress on the transfer. In the present study, we used an achilles tendon allograft to avoid the morbidity of the donor site and reduce the intraoperative time of graft harvesting. To the best of our knowledge, only Chalmers et al have previously published results of a small patient cohort (n = 10), with scapular winging due to LTN palsy that underwent PM transfer with an achilles allograft.²

Irrespective of the chosen technique, a recent systematic review reported significant improvements in shoulder function, pain scores, and shoulder scores after PM transfer for LTN palsy after a median follow-up of 32 months, indicating that PM transfer is an excellent option for patients not recovering after nonsurgical management.⁸ However, no studies that were included in this review described the long-term outcomes, with the longest mean follow-up being approximately 5 years.²⁴ Long-term outcomes are, however, particularly important in this specific patient population, as most patients are relatively young at the time of the onset of the disease. Information on the long-term improvement of shoulder function and its associated impact on QoL is useful for both orthopedic surgeons and patients during counselling, thus for better handling of patient expectations.

The mean VAS pain scores in the present study (ie, 2.0 at rest and 2.9 during motion, 10 being excruciating pain) after a median follow-up of 17 years were comparable to postop VAS pain scores found in other studies (mean = 2.9; range 1–4).^{2,3,6,13,24,25} The mean constant scores at the final follow-up were, however, lower: 69 in the present study in comparison with scores between 82 and 85 reported by three other studies.^{4,17,25} Also, the recurrence of scapular winging at the final follow-up was slightly higher in our study (33%) in comparison to other studies (mean 16%, range 0%–60%).⁸ In the present study, forward flexion increased by a mean of 50 degrees 1 year after surgery, which is comparable to the pooled results presented in a systematic review (mean improvement: 47 degrees).⁸ After a median follow-up of 17 years, shoulder forward flexion was on average 20 degrees lower compared to the first postop year, which was still substantially better than preop shoulder function, indicating that functional improvements persist in the long run.

It has been suggested previously to evaluate the effect of surgical intervention by measuring the functional ROM, ie, the minimum required ROM to complete all tasks in daily living, as this is easier to interpret for both patient and surgeon.¹⁴ Namdari et al concluded that to successfully complete all tasks of daily living, approximately 120° forward elevation, 130° abduction, and 60° external rotation in 90° abduction is needed.¹⁵ When interpreting our results in this manner, none of the patients had a functional

ROM preoperatively, while eleven patients (68%) had a functional ROM 1 year postoperatively, and nine patients (56%) still had a functional ROM at the final follow-up. This indicates that even after a median follow-up of 17 years, a substantial part of patients still have sufficient shoulder functionality to perform all daily life activities.

Several factors might explain the relatively high recurrence rate of scapular winging in comparison to other studies and decrease in function when comparing long-term results to 1-year postop function. First, the tendon graft may have ruptured. Secondly, it is also possible that stretching of the graft might decrease shoulder function and lead to recurrence of winging over time. Furthermore, it is possible that patients developed other shoulder pathology limiting shoulder function as a consequence of altered shoulder kinematic patterns due to the PM transfer. Lastly, shoulder function is known to decline with age.¹⁸ The loss in function after a median follow-up of 17 years may be partially attributable to “healthy ageing”.²¹

Our study has some limitations: first, the retrospective study design comes with inherent flaws such as missing data. For that matter, only data on shoulder function were available both pre- and postoperatively, so we could not compare other outcome measures with its baseline values to more directly assess improvement in eg, pain scores or QoL. Secondly, it is a small case series, although this is representative of the rarity of this type of shoulder pathology both in clinical practice and in the literature. Thirdly, no postop imaging (eg, by MRI) was performed to visualize the tendon-bone connection, so we could not ascertain that the tendon transfer remained intact or that patients had developed other shoulder pathology. Lastly, it is possible that scapular winging in some of the patients (eg, the patient with bilateral scapular winging) was caused by a more extensive and complex peripheral nervous system disorder (eg, neuralgic amyotrophy), which could have affected functional outcomes.¹¹ Strengths of the study are its length of follow-up, which to the best of our knowledge is the longest follow-up for PM transfer reported in the literature and its minimal loss to follow-up.

Conclusion

The results of the present study indicate that PM transfer with an achilles tendon allograft augmentation for persistent scapular winging due to LTN palsy results in functional improvements that persist long-term. These functional improvements likely translate to better QoL based on their association. Despite the functional improvements, the present study also showed that scapular winging due to LTN palsy had a substantial impact on the QoL of patients after PM transfer, with scores in

the physical domain lower than for the general Dutch population. The present study adds information on the long-term outcomes of PM transfer for LTN palsy, which can be used to inform patients during a shared decision-making process with their physician in clinical practice.

Disclaimers:

Funding: No funding was disclosed by the authors.

Conflicts of interest: The authors, their immediate families, and any research foundation with which they are affiliated have not received any financial payments or other benefits from any commercial entity related to the subject of this article.

References

- Aaronson NK, Muller M, Cohen PD, Essink-Bot ML, Fekkes M, Sanderman R, et al. Translation, validation, and norming of the Dutch language version of the SF-36 health survey in community and chronic disease populations. *J Clin Epidemiol* 1998;51:1055-68.
- Chalmers PN, Saltzman BM, Feldheim TF, Mascarenhas R, Mellano C, Cole BJ, et al. A comprehensive analysis of pectoralis major transfer for long thoracic nerve palsy. *J Shoulder Elbow Surg* 2015;24:1028-35. <https://doi.org/10.1016/j.jse.2014.12.014>.
- Connor PM, Yamaguchi K, Manifold SG, Pollock RG, Flatow EL, Bigliani LU. Split pectoralis major transfer for serratus anterior palsy. *Clin Orthop Relat Res* 1997;341:134-42.
- Elhassan BT, Wagner ER. Outcome of transfer of the sternal head of the pectoralis major with its bone insertion to the scapula to manage scapular winging. *J Shoulder Elbow Surg* 2015;24:733-40. <https://doi.org/10.1016/j.jse.2014.08.022>.
- Foo CL, Swann M. Isolated paralysis of the serratus anterior. A report of 20 cases. *J Bone Joint Surg Br* 1983;65:552-6.
- Galano GJ, Bigliani LU, Ahmad CS, Levine WN. Surgical treatment of winged scapula. *Clin Orthop Relat Res* 2008;466:652-60. <https://doi.org/10.1007/s11999-007-0086-2>.
- Gartsman GM, Brinker MR, Khan M, Karahan M. Self-assessment of general health status in patients with five common shoulder conditions. *J Shoulder Elbow Surg* 1998;7:228-37.
- Geurkink TH, Gacaferi H, Marang-van de Mheen PJ, Schoones JW, de Groot JH, Nagels J, et al. Treatment of neurogenic scapular winging: a systematic review on outcomes after nonsurgical management and tendon transfer surgery. *J Shoulder Elbow Surg* 2023;32:e35-47. <https://doi.org/10.1016/j.jse.2022.09.009>.
- Gooding BW, Geoghegan JM, Wallace WA, Manning PA. Scapular winging. *Shoulder Elbow* 2014;6:4-11. <https://doi.org/10.1111/sae.12033>.
- Iceton J, Harris WR. Treatment of winged scapula by pectoralis major transfer. *J Bone Joint Surg Br* 1987;69:108-10.
- Ijspeert J, Janssen RMJ, van Alfen N. Neuralgic amyotrophy. *Curr Opin Neurol* 2021;34:605-12. <https://doi.org/10.1097/wco.0000000000000968>.
- Kibler WB, Ludewig PM, McClure PW, Michener LA, Bak K, Sciascia AD. Clinical implications of scapular dyskinesis in shoulder injury: the 2013 consensus statement from the 'Scapular Summit'. *Br J Sports Med* 2013;47:877-85. <https://doi.org/10.1136/bjsports-2013-092425>.
- Lit T, Yang ZZ, Deng Y, Xiao M, Jiang C, Wang JW. Indirect transfer of the sternal head of the pectoralis major with autogenous semitendinosus augmentation to treat scapular winging secondary to long thoracic nerve palsy. *J Shoulder Elbow Surg* 2017;26:1970-7. <https://doi.org/10.1016/j.jse.2017.04.015>.
- Magermans DJ, Chadwick EK, Veeger HE, van der Helm FC. Requirements for upper extremity motions during activities of daily living. *Clin Biomech* 2005;20:591-9. <https://doi.org/10.1016/j.clinbiomech.2005.02.006>.
- Namdari S, Yagnik G, Ebaugh DD, Nagda S, Ramsey ML, Williams GR Jr, et al. Defining functional shoulder range of motion for activities of daily living. *J Shoulder Elbow Surg* 2012;21:1177-83. <https://doi.org/10.1016/j.jse.2011.07.032>.
- Noerdlinger MA, Cole BJ, Stewart M, Post M. Results of pectoralis major transfer with fascia lata autograft augmentation for scapula winging. *J Shoulder Elbow Surg* 2002;11:345-50. <https://doi.org/10.1067/mse.2002.124525>.
- Perlmutter GS, Leffert RD. Results of transfer of the pectoralis major tendon to treat paralysis of the serratus anterior muscle. *J Bone Joint Surg Am* 1999;81:377-84.
- Pike JM, Singh SK, Barfield WR, Schoch B, Friedman RJ, Eichinger JK. Impact of age on shoulder range of motion and strength. *JSES Int* 2022;6:1029-33. <https://doi.org/10.1016/j.jseint.2022.08.016>.
- Pikkariainen V, Kettunen J, Vastamaki M. The natural course of serratus palsy at 2 to 31 years. *Clin Orthop Relat Res* 2013;471:1555-63. <https://doi.org/10.1007/s11999-012-2723-7>.
- Post M. Pectoralis major transfer for winging of the scapula. *J Shoulder Elbow Surg* 1995;4:1-9.
- Raz Y, Henseler JF, Kolk A, Riaz M, van der Zwaal P, Nagels J, et al. Patterns of age-associated degeneration differ in shoulder muscles. *Front Aging Neurosci* 2015;7:236. <https://doi.org/10.3389/fnagi.2015.00236>.
- Seror P, Lenglet T, Nguyen C, Ouaknine M, Lefevre-Colau MM. Unilateral winged scapula: clinical and electrodiagnostic experience with 128 cases, with special attention to long thoracic nerve palsy. *Muscle Nerve* 2018;57:913-20. <https://doi.org/10.1002/mus.26059>.
- Steinmann SP, Wood MB. Pectoralis major transfer for serratus anterior paralysis. *J Shoulder Elbow Surg* 2003;12:555-60. [https://doi.org/10.1016/s1058-2746\(03\)00174-5](https://doi.org/10.1016/s1058-2746(03)00174-5).
- Streit JJ, Lenarz CJ, Shishani Y, McCrum C, Wanner JP, Nowinski RJ, et al. Pectoralis major tendon transfer for the treatment of scapular winging due to long thoracic nerve palsy. *J Shoulder Elbow Surg* 2012;21:685-90. <https://doi.org/10.1016/j.jse.2011.03.025>.
- Tauber M, Moursy M, Koller H, Schwartz M, Resch H. Direct pectoralis major muscle transfer for dynamic stabilization of scapular winging. *J Shoulder Elbow Surg* 2008;17:295-345. <https://doi.org/10.1016/j.jse.2007.08.003>.
- Tubby AH. A case illustrating the operative treatment of paralysis of the serratus magnus by muscle grafting. *Br Med J* 1904;2:1159-60.
- Ware J, Ma K, Keller SD. SF-36 physical and mental health summary scales. In: A user's manual, 8. Boston, MA: The Health Institute, New England Medical Centre; 1993. p. 23-8.
- Warner JJ, Navarro RA. Serratus anterior dysfunction. Recognition and treatment. *Clin Orthop Relat Res* 1998;349:139-48.