

## Magnetic resonance imaging-based ID of the vasculature across the heart–brain axis

Weingärtner, S.D.

**DOI**

[10.1093/eurhartj/ehad265](https://doi.org/10.1093/eurhartj/ehad265)

**Publication date**

2023

**Document Version**

Final published version

**Published in**

European Heart Journal - Cardiovascular Imaging

**Citation (APA)**

Weingärtner, S. D. (2023). Magnetic resonance imaging-based ID of the vasculature across the heart–brain axis. *European Heart Journal - Cardiovascular Imaging*, (1-3). <https://doi.org/10.1093/eurhartj/ehad265>

**Important note**

To cite this publication, please use the final published version (if applicable). Please check the document version above.

**Copyright**

Other than for strictly personal use, it is not permitted to download, forward or distribute the text or part of it, without the consent of the author(s) and/or copyright holder(s), unless the work is under an open content license such as Creative Commons.

**Takedown policy**

Please contact us and provide details if you believe this document breaches copyrights. We will remove access to the work immediately and investigate your claim.

***Green Open Access added to TU Delft Institutional Repository***

***'You share, we take care!' - Taverne project***

**<https://www.openaccess.nl/en/you-share-we-take-care>**

Otherwise as indicated in the copyright section: the publisher is the copyright holder of this work and the author uses the Dutch legislation to make this work public.

## Global Spotlights

# Magnetic resonance imaging-based ID of the vasculature across the heart–brain axis

Sebastian Weingärtner 

Department of Imaging Physics, Delft University of Technology, Lorentzweg 1, 2628CJ Delft, The Netherlands

Failure of the microvasculature is increasingly moving into the spotlight as a new frontier in cardiovascular medicine, underpinning many of today's most burdening diseases.<sup>1</sup> However, a paucity of tools for its non-invasive characterization critically limits our understanding of microvascular diseases. The European Research Council (ERC) has awarded a Start-up Grant to pursue closing this gap. In the *VascularID* project, researchers from the TU Delft are tasked with the development, validation, and demonstration of novel magnetic resonance imaging (MRI)-based tools to quantitatively uncover microvascular properties *in vivo*.

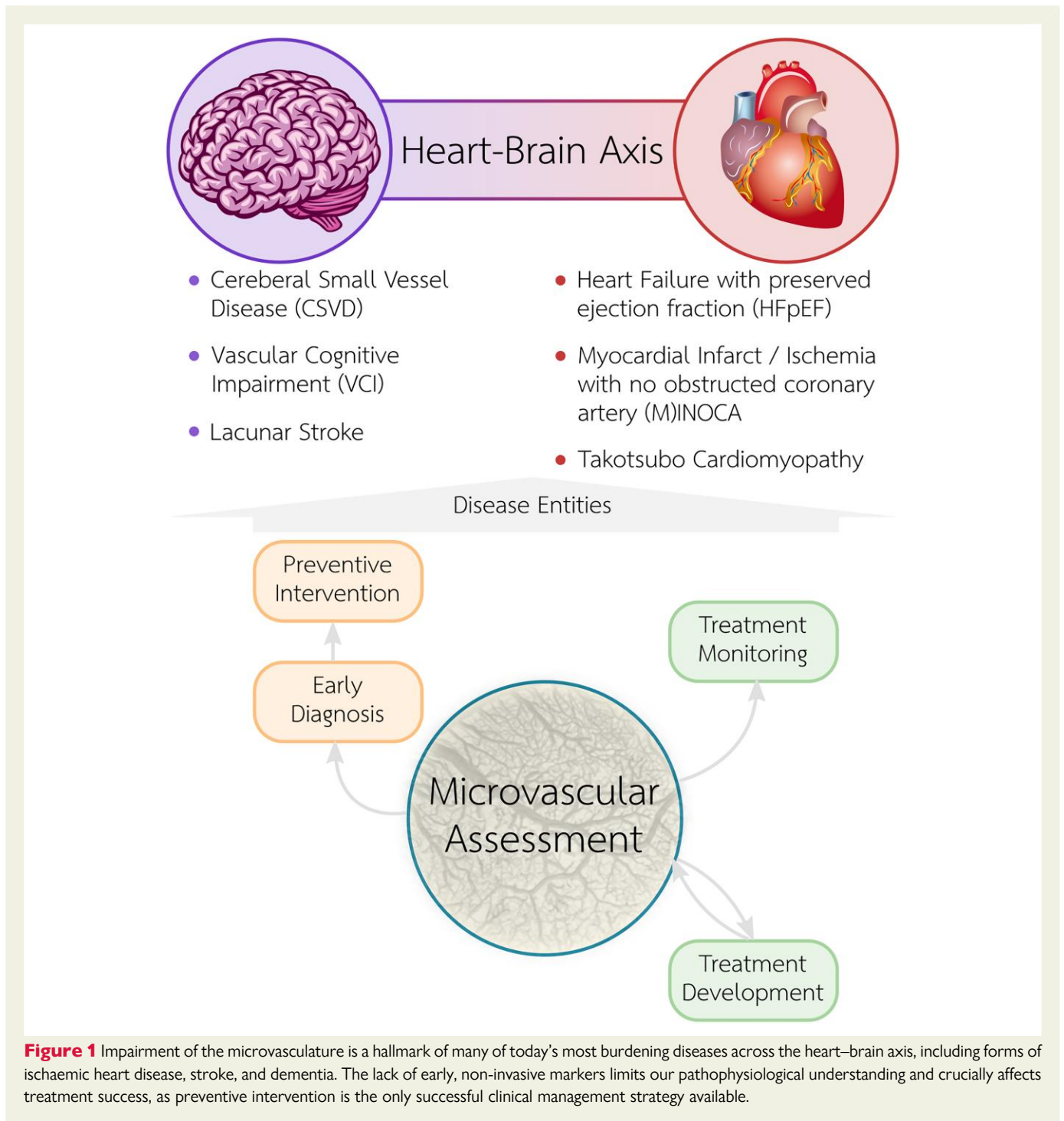
The microvasculature describes the network of small vessels throughout the body, comprising arterioles, venules, and capillaries. While significant progress has been made in the diagnosis and treatment of ischaemic heart disease and ischaemic stroke caused by the occlusion of large arteries, many diseases of the microvasculature remain an open clinical question. About 20%–60% of ischaemic heart disease, stroke, and dementia cases are caused by small vessel disease.<sup>1,2</sup> Cardiovascular disease entities that are thought to be related to microvascular dysfunction, include heart failure with preserved ejection fraction, myocardial infarct/ischaemia with non-obstructive coronary arteries, or Takatsubo (Figure 1). Pathologies of the microvasculature in the brain are described as cerebral small vessel disease and constitute one of the major contributors to vascular cognitive dementia and cognitive decline in the elderly. These cardio- and cerebrovascular diseases often present together and are linked to common comorbidities such as hypertension, diabetes, obesity, or aging.<sup>2</sup> Microvascular rarefaction is a common feature of these comorbidities and is known to precede the onset of symptoms.<sup>3</sup> Thus, the microvasculature is increasingly moving into the focus of cardiovascular research and takes centre stage in the search for the link, explaining the connection between disease entities of the heart and the brain (the heart–brain axis).<sup>4</sup>

Our understanding of the (patho)physiology has always been intimately linked to the availability of tools for its observation, dating back all the way to Antoni van Leeuwenhoek's account of the red blood cells in the latter half of the 17th century. For example, occlusion of large arteries can be directly visualized with various medical imaging modalities. Ischaemic events in the heart or the brain that result from these

occlusions are well characterized and understood, their diagnosis is reliable and treatment options are plentiful. With diameters down to <10 µm, large parts of the microvasculature escape direct detection with current medical imaging technology, due to limitations in the attainable imaging resolution. Thus, to date, a comprehensive assessment of the microvasculature can only be achieved with histology. *In vivo*, this requires an invasive sample biopsy, which can rarely be obtained. The lack of non-invasive tools greatly hinders our understanding of the pathophysiology and consequently limits the treatment options for microvascular disease after the onset of symptoms.<sup>4</sup> Early interventions, including preventive lifestyle changes, present a central strategy for clinical management, but a lack of early disease markers hampers patient selection for the best treatment and evaluation of interventions. Comprehensive non-invasive characterization of the microvasculature is needed to advance therapeutic developments and facilitate selective, preventive interventions.

Magnetic resonance imaging is a mainstay in clinical radiology and is gaining an increasing foothold in cardiovascular medicine in recent years.<sup>5</sup> While its imaging resolution remains limited compared with CT, the strength of MRI lies in the unparalleled, wide spectrum of contrast information. Physical phenomena from the nano- to the macroscopic scale contribute to the signal strength in MRI and give rise to a plethora of imaging contrasts enabling in-depth tissue characterization. As a result, MRI can depict a macroscopic ensemble average of microscopic phenomena. Clinically established examples include the measurement of microscopic displacement in diffusion MRI or the indirect detection of macromolecules in chemical exchange saturation transfer.

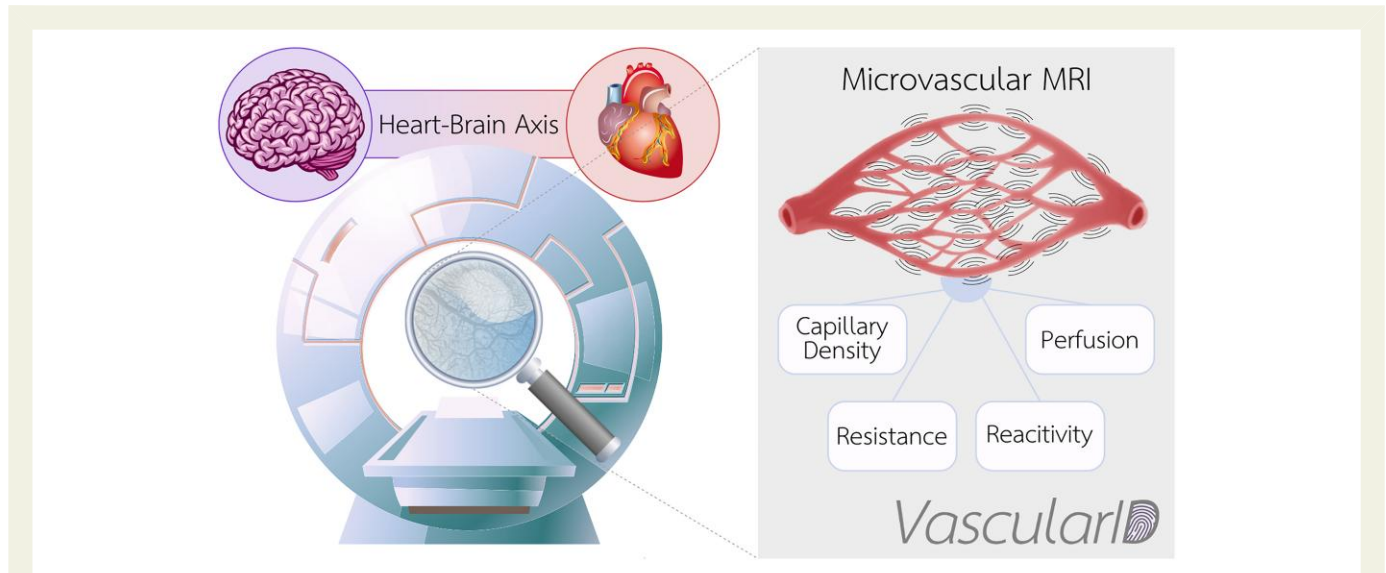
Another rich source of contrast has been found in the susceptibility difference between deoxygenated blood and surrounding tissue. First described as the blood oxygenation level-dependent (BOLD) effect by Ogawa et al.,<sup>6</sup> BOLD became widely used in a range of MRI applications. Most notably functional MRI (fMRI) uses the BOLD effect to detect neural activity. Susceptibility-weighted imaging is also increasingly gaining attention for the visualization of mesoscopic vessels in MRI.<sup>7</sup> Seminal research has been carried out modelling the susceptibility fields around the microvasculature to quantitatively describe their



contributions to the MRI signal and the BOLD effect.<sup>8,9</sup> Such models enabled a validated estimation of the blood oxygen extraction fraction and the venous blood volume. In combination with exogenous contrast agents, this has been shown to allow for the estimation of a blood-volume weighted vessel size average.<sup>10</sup> These techniques are examples of the promising window that susceptibility effects provide in uncovering microvascular properties *in vivo*.

The *VascularID* project builds a research line to explore the potential of susceptibility effects for quantitative assessment of microvascular properties across the heart–brain axis (Figure 2). In this research

programme, researchers from the TU Delft aim to develop new approaches to leverage the susceptibility fields created in microvascular vessel networks and derive quantitative imaging biomarkers for the use of cardio- and cerebrovascular diseases. Existing and novel MRI techniques will be combined in an attempt to provide an imaging suite for a comprehensive assessment of the microvasculature. Thorough investigation and metrological characterization of those imaging biomarkers will be pursued. State-of-the-art microprinting will be used to generate well-controlled environments of characteristic susceptibility fields to validate the physical signal models. Animal models allow for



**Figure 2** Magnetic resonance imaging (MRI) has an imaging resolution multiple orders of magnitude larger than the size of the microvasculature. Nonetheless, physical interactions of the hydrogen nuclei constituting the source of the magnetic resonance imaging signal can unlock comprehensive characterization of the microvascular vessel network across the heart–brain axis *in vivo*. This figure has been designed using assets from Freepik.com.

*in vivo* validation against whole organ histology and can shed unique light on the biological sensitivity of the imaging biomarkers. Inching towards clinical qualification, comprehensive testing in healthy subjects, and demonstration of clinical feasibility in relevant patient populations across the heart–brain axis will fortify the imaging toolbox for large-scale evaluation in the clinic.

Continuous advances in MR imaging physics and technology have put us in a position to exploit the subtle characteristics of microvascular susceptibility fields *in vivo*. This may provide a seminal approach toward the characterization of microvascular diseases. Supported by an ERC Start-Up grant this project attempts to provide new tools for the study of microvascular pathophysiological processes. At a time when microvascular diseases emerge as a new frontier in cardiovascular medicine, it may equip cardiovascular researchers and practitioners with the much-needed tools to take on one of the major healthcare challenges of our time.

## Data availability

No new data were generated or analysed in support of this research.

## Conflict of interest

All authors declare no conflict of interest for this contribution.

## Funding

This project has been approved for funding by the European Union in form of a European Research Council Starting Grant (VascularID, ERC StG

101078711). Views and opinions expressed are however those of the author only and do not necessarily reflect those of the European Union or the European Research Council Executive Agency. Neither the European Union nor the granting authority can be held responsible for them.

## References

- Berry C, Duncker DJ. Coronary microvascular disease: the next frontier for cardiovascular research. *Cardiovasc Res* 2020;**116**:737–740. <https://doi.org/10.1093/cvr/cvaa035>
- Evans LE, Taylor JL, Smith CJ, Pritchard HAT, Greenstein AS, Allan SM. Cardiovascular comorbidities, inflammation, and cerebral small vessel disease. *Cardiovasc Res* 2021;**117**: 2575–2588.
- Noon JP, Walker BR, Webb DJ, Shore AC, Holton DW, Edwards HV, et al. Impaired microvascular dilatation and capillary rarefaction in young adults with a predisposition to high blood pressure. *J Clin Invest* 1997;**99**:1873–1879. <https://doi.org/10.1172/JCI119354>
- Berry C, Sidik N, Pereira AC, Ford TJ, Touyz RM, Kaski J-C, et al. Small-vessel disease in the heart and brain: current knowledge, unmet therapeutic need, and future directions. *J Am Heart Assoc* 2019;**8**:e011104. <https://doi.org/10.1161/JAHA.118.011104>
- Leiner T, Bogaert J, Friedrich MG, Mohiaddin R, Muthurangu V, Myerson S, et al. Scmr position paper (2020) on clinical indications for cardiovascular magnetic resonance. *J Cardiovasc Magn Res* 2020;**22**:76. <https://doi.org/10.1186/s12968-020-00682-4>
- Ogawa S, Lee TM, Kay AR, Tank DW. Brain magnetic resonance imaging with contrast dependent on blood oxygenation. *Proc Natl Acad Sci USA* 1990;**87**:9868–9872. <https://doi.org/10.1073/pnas.87.24.9868>
- Cho ZH, Ro YM, Lim TH. Nmr venography using the susceptibility effect produced by deoxyhemoglobin. *Magn Reson Med* 1992;**28**:25–38. [https://doi.org/10.1002/\(ISSN\)1522-2594](https://doi.org/10.1002/(ISSN)1522-2594)
- He X, Yablonskiy DA. Quantitative bold: mapping of human cerebral deoxygenated blood volume and oxygen extraction fraction: default state. *Magn Reson Med* 2007;**57**:115–126. [https://doi.org/10.1002/\(ISSN\)1522-2594](https://doi.org/10.1002/(ISSN)1522-2594)
- Buschle LR, Kurz FT, Kampf T, Schlemmer HP, Ziener CH. Spin dephasing around randomly distributed vessels. *J Magn Reson (San Diego, Calif.: 1997)* 2019;**299**:12–20. <https://doi.org/10.1016/j.jmr.2018.11.014>
- Kiselev VG, Strecker R, Ziyeh S, Speck O, Hennig J. Vessel size imaging in humans. *Magn Reson Med* 2005;**53**:553–563. [https://doi.org/10.1002/\(ISSN\)1522-2594](https://doi.org/10.1002/(ISSN)1522-2594)