

**Trigonometric algorithm defining the true three-dimensional acetabular cup orientation  
Correlation between measured and calculated cup orientation angles**

Snijders, T.E.; Schlösser, Tom P.C.; van Gaalen, S.M.; Castelein, R.M.; Weinans, Harrie; de Gast, A.

**DOI**

[10.2106/JBJS.OA.17.00063](https://doi.org/10.2106/JBJS.OA.17.00063)

**Publication date**

2018

**Document Version**

Final published version

**Published in**

JBJS Open Access

**Citation (APA)**

Snijders, T. E., Schlösser, T. P. C., van Gaalen, S. M., Castelein, R. M., Weinans, H., & de Gast, A. (2018). Trigonometric algorithm defining the true three-dimensional acetabular cup orientation: Correlation between measured and calculated cup orientation angles. *JBJS Open Access*, 3(3), Article e0063. <https://doi.org/10.2106/JBJS.OA.17.00063>

**Important note**

To cite this publication, please use the final published version (if applicable).  
Please check the document version above.

**Copyright**

Other than for strictly personal use, it is not permitted to download, forward or distribute the text or part of it, without the consent of the author(s) and/or copyright holder(s), unless the work is under an open content license such as Creative Commons.

**Takedown policy**

Please contact us and provide details if you believe this document breaches copyrights.  
We will remove access to the work immediately and investigate your claim.

# Trigonometric Algorithm Defining the True Three-Dimensional Acetabular Cup Orientation

## Correlation Between Measured and Calculated Cup Orientation Angles

T.E. Snijders, MD, T.P.C. Schlösser, MD, PhD, S.M. van Gaalen, MD, PhD, R.M. Castelein, MD, PhD, H. Weinans, PhD, and A. de Gast, MD, PhD

*Investigation performed at Diakonessenhuis Zeist, Zeist, the Netherlands.*

**Background:** Acetabular cup orientation plays a key role in implant stability and the success of total hip arthroplasty. To date, the orientation has been measured with different imaging modalities and definitions, leading to lack of consensus on optimal cup placement. A 3-dimensional (3D) concept involving a trigonometric description enables unambiguous definitions. Our objective was to test the validity and reliability of a 3D trigonometric description of cup orientation.

**Methods:** Computed tomographic scans of the pelvis, performed for vascular assessment of 20 patients with 22 primary total hip replacements in situ, were systematically collected. On multiplanar reconstructions, 3 observers independently measured cup orientation retrospectively in terms of coronal inclination, sagittal tilt, and transverse version. The angles measured in 2 planes were used to calculate the angle in the third plane via a trigonometric algorithm. For correlation and reliability analyses, intraobserver and interobserver differences between measured and calculated angles were evaluated with use of the intraclass correlation coefficient (ICC).

**Results:** Measured and calculated angles had ICCs of 0.953 for coronal inclination, 0.985 for sagittal tilt, and 0.982 for transverse version. Intraobserver and interobserver reliability had ICCs of 0.987 and 0.987, respectively, for coronal inclination; 0.979 and 0.981, respectively, for sagittal tilt; and 0.992 and 0.978, respectively, for transverse version.

**Conclusions:** The 3D concept with its trigonometric algorithm is a valid and reliable tool for the measurement of cup orientation.

**Clinical Relevance:** By calculating the transverse version of cups from coronal inclination and sagittal tilt measurements, the trigonometric algorithm enables a 3D definition of cup orientation, regardless of the imaging modality used. In addition, it introduces sagittal tilt that, like pelvic tilt, rotates around the transverse axis.

The first total hip arthroplasty, introduced in 1962 by Sir John Charnley, had a dislocation rate of approximately 4.8% after 23 years, as reported in a large long-term cohort<sup>1</sup>. Since then, dislocation has remained one of the most common postoperative complications, with reported rates of 0.2% after 3 months, 0.8% after 1 year, and 4.76% after 10 years<sup>2-4</sup>. It is well known that acetabular cup orientation is of substantial importance to a well-functioning and stable total hip replacement<sup>5-7</sup>. Several studies have suggested

that cup orientation should be within a specific zone in order to minimize the risk of dislocation. For instance, the widely accepted “safe zone” of Lewinnek is characterized by an inclination of  $40^\circ \pm 10^\circ$  and an anteversion of  $15^\circ \pm 10^\circ$ . However, multiple methods for measuring cup orientation, involving different imaging modalities and various definitions for descriptive angles in different planes, have been introduced<sup>7-10</sup>. On the one hand, “inclination” is consistently considered to be the angle that represents cup orientation in

**Disclosure:** This study was funded by the Clinical Orthopedic Research Foundation – mN. The **Disclosure of Potential Conflicts of Interest** forms are provided with the online version of the article (<http://links.lww.com/JBJSOA/A49>).

Copyright © 2018 The Authors. Published by The Journal of Bone and Joint Surgery, Incorporated. All rights reserved. This is an open-access article distributed under the terms of the [Creative Commons Attribution-Non Commercial-No Derivatives License 4.0 \(CCBY-NC-ND\)](https://creativecommons.org/licenses/by-nc-nd/4.0/), where it is permissible to download and share the work provided it is properly cited. The work cannot be changed in any way or used commercially without permission from the journal.

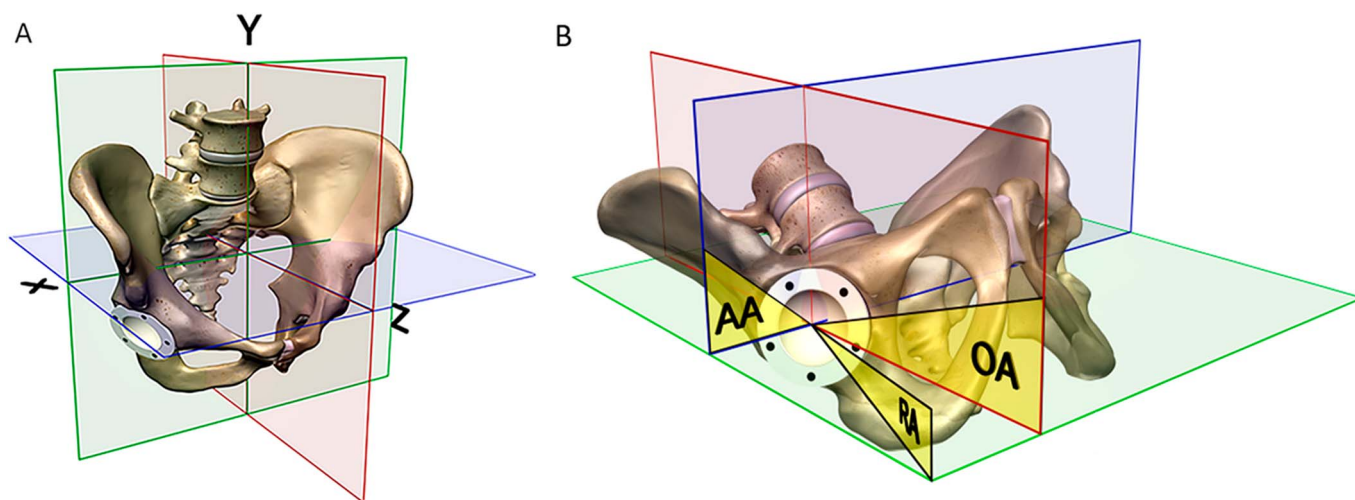


Fig. 1  
**Fig. 1-A** Illustration depicting the coronal plane (green), sagittal plane (red), and transverse plane (blue). X indicates the transverse axis, Y indicates the longitudinal axis, and Z indicates the sagittal axis. **Fig. 1-B** Illustration depicting the different definitions of anteversion introduced by Murray<sup>10</sup>. AA = anatomical anteversion in the transverse plane, with rotation around the longitudinal axis; OA = operative anteversion in the sagittal plane, with rotation around the transverse axis; and RA = radiographic anteversion in a projectional plane, with rotation around an axis in between the longitudinal and transverse axes.

the anatomical coronal plane. On the other hand, “anteversion” has been used to describe cup orientation in the anatomical transverse and sagittal planes as well as in different oblique planes<sup>11</sup>. For example, “anteversion” was measured on radiographs in the sagittal plane and on computed tomography (CT) scans in the transverse plane. It was measured on cross-lateral radiographs on a projectional plane or calculated from the ellipse that results from the cup projection on anteroposterior pelvic radiographs. In addition, a combination between the sagittal and transverse angles has been used intraoperatively<sup>12-15</sup>. Several of these methods disregard the fact that these measured angles are projections of a 3-dimensional (3D) cup on different 2-dimensional (2D) planes. In a recent study, Snijders et al. showed that a plethora of different definitions of anteversion for cup orientation leads to confusion with respect to guidelines for cup placement<sup>16</sup>. As there is no uniform

method for the assessment of cup orientation in 3 dimensions, it is very difficult to compare or pool data from studies on the optimal cup position<sup>6,7,17</sup>. A uniform concept that is applicable with every 2D and 3D imaging method could fill this void.

Three-dimensional cup orientation can be defined and measured in the coronal, transverse, and sagittal planes (Fig. 1). Each angle rotates around an axis perpendicular to that particular plane. Thus, cup orientation can be defined by angles that describe inclination as the rotation around the sagittal axis in the coronal plane, version as the angle rotating around the longitudinal axis in the transverse plane, and tilt as the angle rotating around the transverse axis in the sagittal plane (Fig. 2, Video 1). Evaluation of cup orientation in the sagittal plane is highly recommended. First, adequate inclination and anteversion within the “safe zone” of Lewinnek could still be insufficient in the sagittal plane. Second, high-risk movements

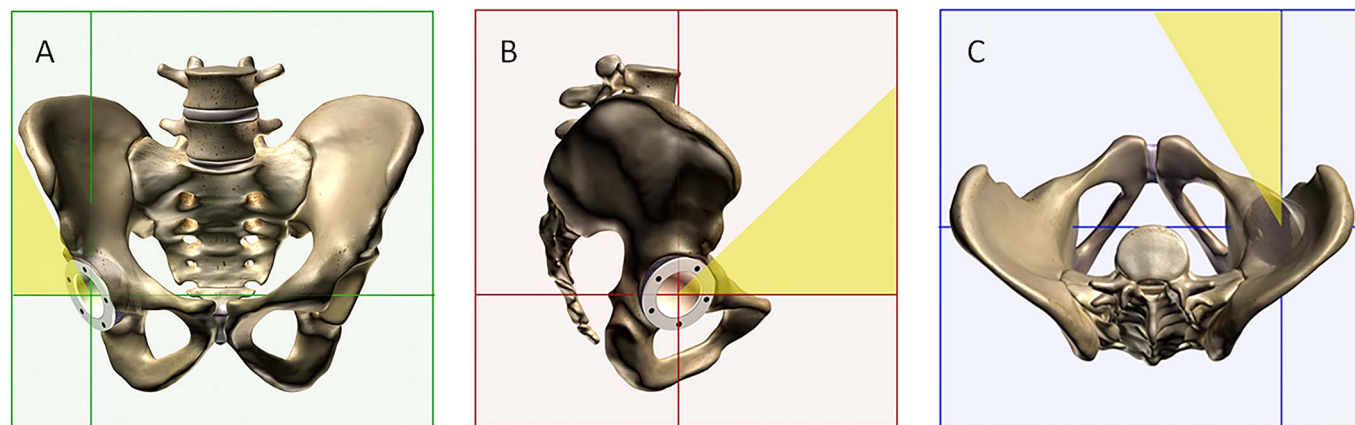


Fig. 2  
 Illustrations depicting coronal inclination (**Fig. 2-A**), sagittal tilt (**Fig. 2-B**), and transverse version (**Fig. 2-C**) of the cup.

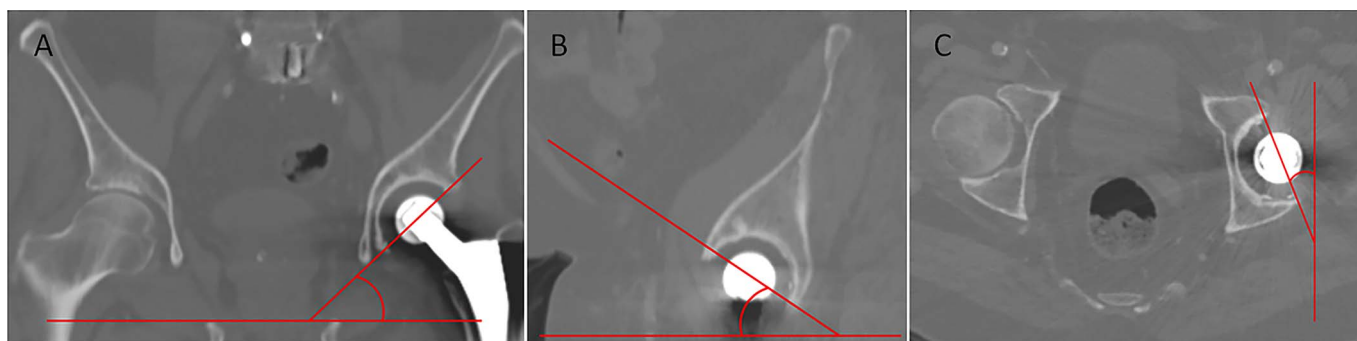


Fig. 3  
Multiplanar reconstruction of CT scans, illustrating the method of measurement of coronal inclination (Fig. 3-A), sagittal tilt (Fig. 3-B), and transverse version (Fig. 3-C) of the acetabular cup.

for a posterior dislocation often consist of adduction and hip flexion, with the latter movement involving rotation around the transverse axis in the sagittal plane. Third, pelvic tilt also involves rotation around the transverse axis and solely affects relative 3D cup orientation.

For the present study, we developed a mathematical algorithm that describes the relationships between the 3D cup-orientation angles in the anatomical planes. Because most modern cups are hemispherical, mathematical modeling could be used to calculate cup orientation in the 3 perpendicular planes. In order to implement this trigonometric mathematical 3D algorithm, it is necessary to examine the effect of measuring errors on the results of the algorithm. Moreover, because radiographic transverse imaging is impossible to achieve, this algorithm can only be verified with 3D CT before it can be applied with 2D radiographic images in daily practice.

The purpose of the present study was to test definitions of cup orientation derived from a trigonometric algorithm defined with respect to the 3 anatomical planes. First, the validity of the algorithm was tested by correlating measured and calculated 3D cup-orientation angles. Second, we evaluated the intraobserver and interobserver reliability of the 3D cup-orientation measurements necessary as input for the algorithm.

**Materials and Methods**

**Study Procedures**

After approval from the institutional review board, the patient archiving and communications system (PACS) was systematically searched for CT angiogram images of the pelvis that were acquired between January 2013 and August 2016 and showed a total hip replacement in situ, a cup with a circumferential reference perpendicular to the cup axis, and complete visualization of the pelvis. The exclusion criteria were previous ipsilateral hip surgery other than primary total hip arthroplasty, malignant disease localized in the pelvis or femur, and images that were part of an incomplete series or that showed substantial contrast artifacts in the region of interest. By protocol, scans were acquired with the patient in the supine position with use of a 16-channel multidetector CT system (Siemens Healthcare; slice thickness, 0.5 mm).

Clinical and radiographic charts were reviewed by 1 observer for inclusion and exclusion, and demographic data were collected.

After manual localization of the center of the femoral head of the total hip replacement on the transverse CT images, multiplanar reconstructions were acquired for the coronal, transverse, and sagittal planes with use of MeVisLab (MeVis Medical Solutions). Next, 3 blinded observers independently

TABLE I Demographic Data	
No. of patients (no. of hips)	20 (22)
No. of female patients	11 (55%)
Age* (yr)	75.7 ± 7.1 (62-88)
Left-sided total hip arthroplasty (no. of hips)	13 (59.1%)
Approach (no. of hips)	
Direct lateral	9
Posterolateral	7
Anterolateral	3
Unknown	3
Type of cup (no. of hips)	
RM Pressfit cup (Mathys Bettlach)	17 (77.3%)
PF (Zimmer)	1 (4.5%)
Morscher (Zimmer)	1 (4.5%)
Exeter all-polyethylene cup (Stryker)	1 (4.5%)
Monoblock cup of unknown design	2 (9.1%)
Cup fixation (no. of hips)	
Cemented	3 (13.6%)
Uncemented	19 (86.4%)
Cup type (no. of hips)	
Monoblock	22 (100%)
Modular system	0 (0%)
Cup size† (mm)	54 (46-60)

\*The values are given as the mean and the standard deviation, with the range in parentheses. †The values are given as the median, with the range in parentheses.

**TABLE II Measured and Calculated Values of Coronal Inclination\***

Case	Coronal Inclination (deg)					
	Observer 1		Observer 2		Observer 3	
	Measured	Calculated	Measured	Calculated	Measured	Calculated
1	30.83	31.87	30.63	31.01	30.31	30.63
2	38.31	39.75	37.81	39.79	39.75	39.27
3	52.22	51.30	51.66	50.76	51.94	50.44
4	64.21	65.14	63.36	63.74	63.20	64.58
5	46.2	44.43	44.24	54.75	46.72	52.39
6	43.23	42.72	44.38	42.06	43.80	44.32
7	38.65	38.77	39.73	39.73	39.26	37.50
8	36.42	32.98	32.46	33.28	31.52	35.42
9	48.16	47.02	48.20	46.39	47.54	47.56
10	45.25	44.85	45.84	46.65	44.00	42.21
11	28.69	29.52	29.18	29.47	28.76	28.81
12	37.12	38.74	36.73	29.41	37.23	37.32
13	33.07	34.32	31.96	30.97	32.80	33.48
14	46.72	47.01	43.18	45.79	45.68	46.20
15	54.83	52.08	53.40	49.80	52.05	50.06
16	52.70	52.86	52.74	51.23	53.38	52.32
17	26.08	26.83	26.92	39.38	25.76	26.21
18	44.83	42.87	44.63	41.04	43.75	41.05
19	48.04	48.42	48.56	47.88	47.85	45.89
20†	41.62	37.47	45.43	82.17	42.19	27.70
21	41.80	41.91	41.38	40.92	39.54	41.26
22	49.99	50.53	48.96	49.16	49.41	48.64

\*Differences between calculated and measured angles were evaluated with use of the intraclass correlation coefficient (ICC). For coronal inclination, the ICC was 0.953 (95% CI, 0.923-0.971). †Case excluded.

measured the inclination in the coronal plane, tilt in the sagittal plane, and version in the transverse plane for all cups in random order with use of a HOROS Medical Image Viewer (Horos v2.0.2; Horos project). For interobserver reliability, 1 blinded observer measured the angles at 3 different settings within a 2-week interval. Coronal inclination and sagittal tilt were defined as the angle between the line through the longitudinal axis of the ellipse of the rim of the cup and the horizontal, whereas transverse version was defined as the angle between the longitudinal axis of the ellipse of the rim of the cup and the sagittal axis (Fig. 3). Therefore, positive angles represented anterior sagittal tilt (also referred to as antetilt) and anterior transverse version (also referred to as anteversion of the cup). Last, a trigonometric algorithm that was developed in-house for the assessment of 3D cup orientation was used for calculation of the 3D angles (see Appendix). In this algorithm, the angles measured in 2 perpendicular planes were used to calculate the parameter in the third plane. Hence, for each patient, 3 calculations were derived, whereby inclination, version, and tilt were each subsequently determined on the basis of the 2 others. For anteriorly oriented cups, the following equations were used:

1.  $Inclination = \arctan\left(\frac{\tan Version}{\tan Tilt}\right)$
2.  $Version = \arctan(\tan Tilt \times \tan Inclination)$
3.  $Tilt = \arctan\left(\frac{\tan Version}{\tan Inclination}\right)$

For retroverted and retrotilted cup orientations, the following equations were used:

1.  $Inclination = \arctan\left(\frac{\tan(90 - Version)}{\tan(90 - Tilt)}\right)$
2.  $Version = 90 - (\arctan(\tan(90 - Tilt) \times \tan Inclination))$
3.  $Tilt = 90 - \left(\arctan\left(\frac{\tan(90 - Version)}{\tan Inclination}\right)\right)$

**Statistical Analysis**

For practical purposes and calculation of the different angles with use of the algorithm, data were imported into Excel 2010

**TABLE III Measured and Calculated Values of Sagittal Tilt\***

Case	Sagittal Tilt (deg)					
	Observer 1		Observer 2		Observer 3	
	Measured	Calculated	Measured	Calculated	Measured	Calculated
1	27.23	26.29	25.8	25.47	26.75	26.46
2	46.94	45.47	46.46	44.43	46.25	46.74
3	30.34	31.17	30.72	31.54	25.37	26.58
4	28.02	27.03	27.51	27.12	29.12	27.66
5	22.99	24.29	31.53	22.89	25.49	21.31
6	19.59	19.92	19.42	20.92	19.29	18.97
7	48.52	48.40	49.03	49.03	47.4	49.19
8	7.13	8.09	7.66	7.43	7.56	6.53
9	44.1	45.24	43.57	45.38	44.62	44.60
10	20.82	21.09	28.62	27.94	20.08	21.27
11	21.05	20.40	21.3	21.07	21.13	21.09
12	12.33	11.65	10.61	13.92	11.67	11.63
13	12.12	11.57	10.79	11.21	11.35	11.06
14	30.71	30.45	30.71	28.47	30.88	30.42
15	20.99	22.98	18.88	21.26	18.27	19.51
16	34.36	34.21	33.82	35.27	33.87	34.89
17	22.46	21.80	22.77	14.55	22.25	21.85
18	15.01	16.02	15.56	17.53	14.2	15.54
19	25.62	25.33	27.42	27.98	24.6	26.12
20†	-1.5	-1.29	2.76	0.39	-1.39	-1.26
21	16.05	15.99	16.37	16.62	15.55	14.67
22	32.94	32.44	31.66	31.48	31.81	32.51

\*Differences between calculated and measured angles were evaluated with use of the intraclass correlation coefficient (ICC). For sagittal tilt, the ICC was 0.985 (95% CI, 0.975-0.991). †Case excluded.

(Microsoft). Statistical analyses were performed with use of IBM SPSS Statistics 23 (IBM). The continuous angles were assessed and were expressed as the mean and the standard deviation, with the range in parentheses. Box plots were used to identify any outliers. For validity analysis, differences between the measured and calculated angles per case for the 3 observers were assessed with use of the intraclass correlation coefficient (ICC) and corresponding 95% confidence interval (CI) with a 2-way mixed-effects model for absolute agreement. For intra-observer and interobserver reliability, measured and calculated angles were compared within and between the observers with use of the ICC, with a 1-way random-effects model for intraobserver reliability and a 2-way mixed-effects model for interobserver reliability.

**Results**

*Demographics*

Twenty-two total hip replacements on CT scans of 20 patients met the inclusion criteria. All CT angiograms had been requested for vascular assessment. The primary total hip

replacements had been implanted between 2002 and 2016. Demographic characteristics and cup types are shown in Table I.

*Validity and Reliability Analyses*

Data were normally distributed, and there was only 1 outlier. This outlier was excluded because, in this outlier, 2 angles were around 0°. Therefore, the measuring error affected the calculated results to a great extent. The mean coronal inclination, sagittal tilt, and transverse version that were measured on the multiplanar reconstructions for 21 total hip replacements by 3 observers (thus, for 63 measurements), were 42.82° ± 9.18° (range, 25.76° to 64.21°), 25.67° ± 11.09° (range, 7.13° to 49.03°), and 27.05° ± 12.01° (range, 10.75° to 54.79°), respectively. The calculated angles were 42.90° ± 8.95° (range, 26.21° to 65.14°) for coronal inclination, 25.55° ± 11.09° (range, 6.53° to 49.19°) for sagittal tilt, and 27.26° ± 12.34° (range, 9.62° to 54.74°) for transverse version. Tables II, III, and IV show the measured and calculated angles per case and per observer.

Correlation analysis of 63 measured and calculated 3D angles revealed an ICC of 0.953 (95% CI, 0.923 to 0.971) for

**TABLE IV Measured and Calculated Values of Transverse Version\***

Case	Transverse Version (deg)					
	Observer 1		Observer 2		Observer 3	
	Measured	Calculated	Measured	Calculated	Measured	Calculated
1	39.61	40.77	38.81	39.23	40.41	40.77
2	52.15	53.56	51.64	53.60	51.95	51.47
3	25.12	24.40	25.89	25.17	21.39	20.37
4	13.85	14.42	14.41	14.64	14.83	15.72
5	23.4	22.14	23.44	32.21	20.17	24.18
6	21.08	20.74	21.34	19.81	19.72	20.05
7	54.62	54.74	54.18	54.18	54.79	53.07
8	10.91	9.62	11.58	11.94	10.57	12.21
9	42.08	40.95	42.18	40.38	42.06	42.08
10	20.92	20.65	27.25	27.92	21.95	20.73
11	34.2	35.12	34.6	34.92	35.1	35.15
12	15.24	16.11	18.38	14.09	15.16	15.21
13	17.46	18.25	17.62	16.99	16.88	17.30
14	28.97	29.22	30.02	32.33	29.83	30.28
15	16.64	15.13	16.12	14.25	15.45	14.44
16	27.38	27.51	28.28	27.00	27.4	26.51
17	39.26	40.18	27.08	39.58	39.73	40.29
18	16.11	15.10	17.74	15.75	16.2	14.81
19	23.05	23.32	25.13	24.61	23.93	22.51
20†	-1.15	-1.33	0.38	2.72	-0.73	-0.81
21	17.77	17.84	18.72	18.44	17.6	18.63
22	28.08	28.54	28.06	28.23	28.64	27.99

\*Differences between calculated and measured angles were evaluated with use of the intraclass correlation coefficient (ICC). For transverse version, the ICC was 0.982 (95% CI, 0.971-0.989). †Case excluded.

**TABLE V Results of Intraobserver Reliability Analysis\***

Parameter	Measurement 1† (deg)	Measurement 2† (deg)	Measurement 3† (deg)	ICC‡
Coronal inclination	43.14 ± 9.16 (26.08-64.21)	42.95 ± 9.10 (26.04-64.08)	42.90 ± 8.84 (27.02-63.55)	0.987 (0.974-0.994)
Sagittal tilt	24.45 ± 12.41 (-1.50-48.52)	24.39 ± 12.42 (-1.82-48.14)	24.70 ± 12.35 (-0.72-47.17)	0.979 (0.959-0.991)
Transverse version	25.76 ± 13.49 (-1.15-54.62)	25.79 ± 13.47 (-0.77-53.86)	26.36 ± 13.49 (-0.74-54.16)	0.992 (0.983-0.996)

\*Differences between multiple measurements made by one observer were evaluated with use of the intraclass correlation coefficient (ICC). †The values are given as the mean and the standard deviation, with the range in parentheses. ‡The values are given as the ICC, with the 95% CI in parentheses.

**TABLE VI Results of Interobserver Reliability Analysis\***

Parameter	Observer 1† (deg)	Observer 2† (deg)	Observer 3† (deg)	ICC‡
Coronal inclination	43.14 ± 9.16 (26.08-64.21)	42.79 ± 9.05 (26.92-63.36)	42.57 ± 9.13 (25.76-63.20)	0.987 (0.974-0.994)
Sagittal tilt	24.45 ± 12.41 (-1.50-48.52)	25.13 ± 12.29 (0.38-49.03)	23.91 ± 12.32 (-1.39-47.40)	0.981 (0.962-0.991)
Transverse version	25.76 ± 13.49 (-1.15-54.62)	26.04 ± 2.76 (2.76-54.18)	25.59 ± 13.68 (-0.73-54.79)	0.978 (0.956-0.990)

\*Differences between multiple measurements made by 1 observer were evaluated with use of the intraclass correlation coefficient (ICC). †The values are given as the mean and the standard deviation, with the range in parentheses. ‡The values are given as the ICC, with the 95% CI in parentheses.

coronal inclination, 0.985 (95% CI, 0.975 to 0.991) for sagittal tilt, and 0.982 (95% CI, 0.971 to 0.989) for transverse version (Tables II, III, and IV). The ICCs for intraobserver and interobserver reliability of the measured angles for 21 total hip replacements were 0.987 (95% CI, 0.974 to 0.994) and 0.987 (95% CI, 0.974 to 0.994), respectively, for coronal inclination; 0.979 (95% CI, 0.959 to 0.991) and 0.981 (95% CI, 0.962 to 0.991), respectively, for sagittal tilt; and 0.992 (95% CI, 0.983 to 0.996) and 0.978 (95% CI, 0.956 to 0.990), respectively, for transverse version (Tables V and VI).

## Discussion

The present study showed excellent correlation between measured and calculated angles for the assessment of 3D cup orientation with respect to the 3 anatomical perpendicular planes (Figs. 1 and 2). The proposed trigonometric algorithm can calculate the “true” (gold standard) transverse version in a valid and reliable way on the basis of the coronal inclination and the sagittal tilt. Similarly, coronal inclination can be calculated from sagittal tilt and transverse version, and sagittal tilt can be calculated from coronal inclination and transverse version. Theoretically, the ICC should be 1 in the case of perfect readings, and, in the present study, the ICC approached 1 for all 3 calculated angles (Tables II, III, and IV). The data suggest that the algorithm is usable in everyday practice. The minor measurement error of the readings is clinically irrelevant. An exception in the present study was the outlier case in which both transverse version and sagittal tilt were around 0°. In that case, the minor measuring error affected the proportion between the 2 angles greatly, giving a result ranging from 27.70° to 82.17° of coronal inclination (Tables II, III, and IV). Therefore, we recommend using the algorithm with caution in cases in which 2 angles are approaching 0°.

The validity of this 3D concept provides improvements for the evaluation of optimal cup positioning in total hip arthroplasty and offers great potential for future comparative studies. The definitions are applicable to both radiographic and CT imaging as long as 2 orthogonal projections can be acquired (radiographs) or simulated (CT). While a craniocaudal radiograph of the pelvis is technically impossible, the algorithm has the potential to accurately calculate the transverse version with use of cup orientation angles on 2 radiographs, allowing for easily accessible postoperative feedback. Anteroposterior and lateral radiographs have to be made following the recommendation of Tannast et al.<sup>18</sup>. Specifically, standardized radiographs must be made with the patient in the standing position with the generator at 1.20 m and with the central beam directed to the midpoint between the upper border of the symphysis and the center between both anterior superior iliac spines. The lateral radiograph should be centered on the cranial tip of the contralateral greater trochanter, with the total hip replacement near the detector. After measurement of the sagittal tilt and coronal inclination, the transverse version can be calculated with use of equation number 2 for anteriorly oriented cups, as described in the Materials and Methods section (Fig. 4). The diverging radiation beam, however, presumably results in a larger measuring error. A future study should validate if the algorithm is also applicable with radiographs. If so, then these practical measurements can be performed without the extra radiation and additional cost of CT imaging, making 3D evaluation of cup orientation available for large cohorts. Moreover, the 3D concept could be helpful for establishing a consensus by enabling pooling of different studies that evaluate cup orientation in 2 orthogonal planes.

Murray, in 1993, clearly showed that the definitions for inclination and “anteversion” depend on the evaluation method

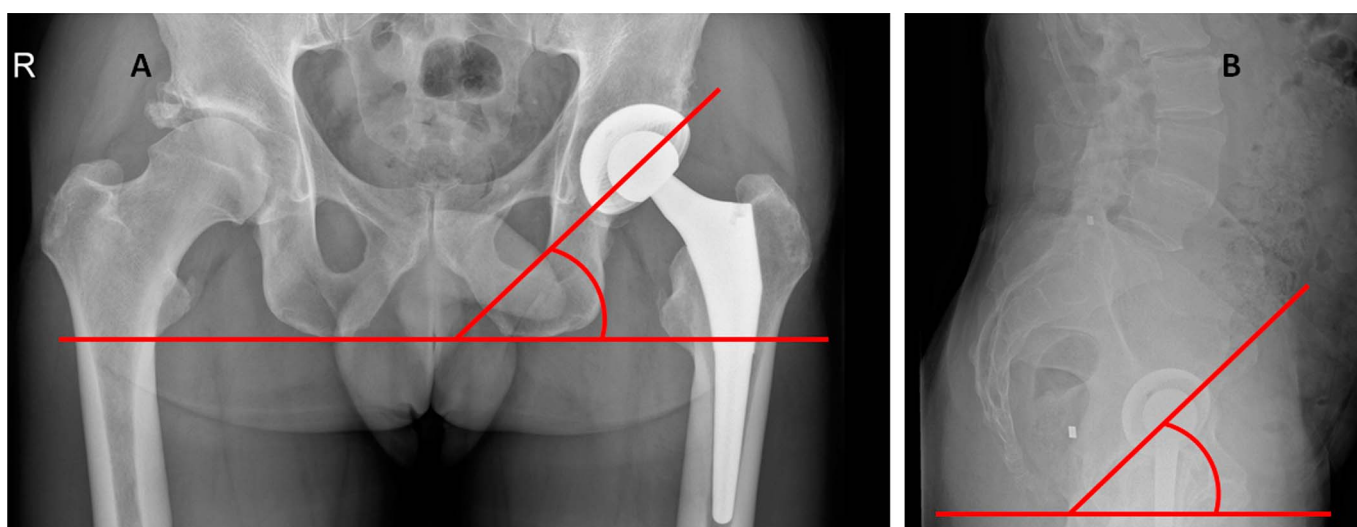


Fig. 4  
Anteroposterior and lateral radiographs illustrating an example of how to calculate transverse version on the basis of coronal inclination and sagittal tilt according to the equation for anteriorly oriented cups as described in the Materials and Methods section:

$$\text{Version} = \arctan(\tan \text{Tilt} \times \tan \text{Inclination})$$

$$\text{Version} = 39.6^\circ = \arctan(\tan 39.2 \times \tan 44.6)$$



used (radiographic, anatomical, and direct observation at surgery)<sup>10</sup>. Direct comparison of inclination is possible because the definitions introduced by Murray for the 3 perspectives are basically equal. On the contrary, the different definitions of anteversion, which represent distinct spatial angles, are not interchangeable (Fig. 1)<sup>10</sup>. The transverse “anteversion” angle is a different spatial angle than the sagittal “anteversion” angle. Unfortunately, many previous studies have involved the use of different imaging methods and different definitions for anteversion, making it difficult to compare the recommendations<sup>6,7,13,14,19-21</sup>. Subsequent meta-analyses evaluating cup anteversion pooled these different outcomes of the spatial angles<sup>22-27</sup>. Thus, there is a lack of consensus for optimal cup orientation<sup>16</sup>. A consensus definition for preoperative planning, intraoperative placement, and postoperative evaluation of cup orientation would be useful. We recommend the evaluation of cup orientation in all 3 anatomical planes. These definitions are also applicable intraoperatively. These spatial angles provide unambiguous definitions and are interchangeable between different imaging modalities.

Moreover, there are reasons to believe that malplacement around the transverse axis is important for the mechanism of dislocation. If the cup orientation is in the “safe zone” of Lewinnek for inclination and anteversion, it might not be “safe” enough for sagittal tilt (Fig. 5). Most hip and pelvic movements (pelvic tilt as well as hip flexion and extension) take place around the transverse axis. Opposing pelvic movements around the transverse axis could be protective against dislocation during certain hip movements. For example, posterior pelvic tilt enhances the containment of the femoral head when there is also hip flexion. The joint reaction forces remain more opposed to each other. However, there is a wide variety between patients in terms of the dynamics of anterior and posterior pelvic tilt<sup>28</sup>. In addition, the amount of pelvic tilt in particular positions differs widely<sup>28</sup>. Theoretically, 1° of anterior pelvic tilt decreases the sagittal tilt of the cup by 1°. In a previous study, Lembeck et al. stated that 1° of pelvic tilt affected anteversion by 0.7°<sup>29</sup>. On the basis of our validated algorithm, however, that statement is not correct. Pelvic tilt changes the amount of transverse version depending on the amounts of coronal inclination and pelvic tilt and follows a tangential function (i.e., equation 2 for anteriorly oriented cups as described in the Materials and Methods section) (Fig. 5). From a kinematic point of view, there is no argument for neglecting the sagittal tilt. Thus, this 3D concept has important clinical relevance for defining the orientation around the transverse axis.

This 3D concept has some limitations when used for the analysis of cup positioning. First, the algorithm cannot be applied to cups that lack a circumferential reference perpendicular to the acetabular axis. Fortunately, almost all modern cups have a circular wire that provides this reference.

A second limitation is that the trigonometric algorithm is only applicable for planes that are perfectly orthogonal. Consequently, cross-lateral views cannot be used. On the other hand, innovative biplanar radiography techniques provide

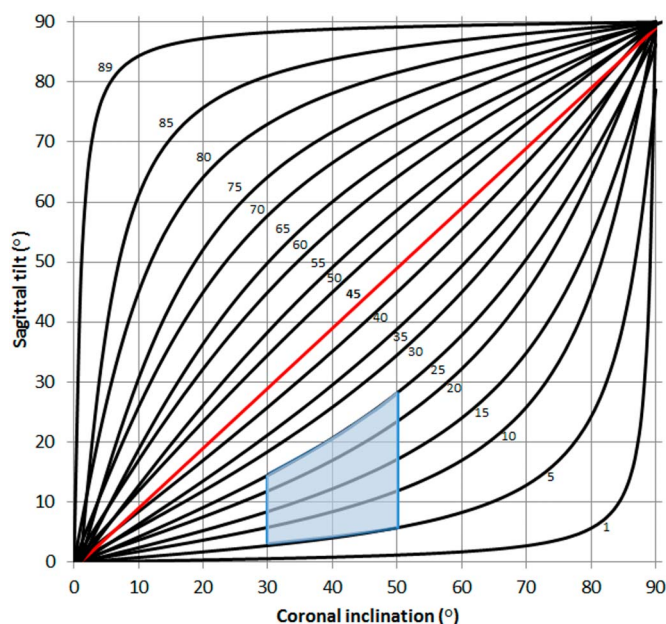


Fig. 5

Three-dimensional surface diagram demonstrating the mathematical interrelation between coronal inclination, sagittal tilt, and transverse version. If 1 of the angles is 45°, the other 2 angles are identical. The red line demonstrates the direct comparison of sagittal tilt and transverse version at a coronal inclination of 45°. The blue area demonstrates the “safe zone” of Lewinnek.

opportunities to use this algorithm for the systematic assessment of 3D cup orientation in patients undergoing total hip arthroplasty. Although additional lateral pelvic radiographs expose the patient to a relative high radiation dose compared with cross-lateral pelvic radiographs, this supplementary radiograph is only required one time postoperatively in addition to the standard anteroposterior pelvic radiograph. In addition, most of these patients are >50 years of age, thereby theoretically diminishing the long-term risk of the higher radiation dose.

A third limitation is that patient positioning has an impact on 3D cup orientation as pelvic tilt changes in different positions<sup>30,31</sup>. Kyo et al. established a difference of <10° of pelvic tilt in 83% to 90% of patients between the standing and supine positions<sup>32</sup>. Measuring and calculating the 3 angles with radiographic imaging with the patient in the standing position might give different results than for the 3 angles in the supine position because of this change in pelvic tilt.

In conclusion, the trigonometric equations provided in the present study can be used to calculate the third 3D orientation angle with use of the orientation angles in the 2 other anatomical planes. Transverse version is often a dominant factor for stability, and this value can now be calculated from the coronal (inclination) and sagittal (tilt) planes. Thus, this 3D concept provides unambiguous definitions of cup orientation regardless of the imaging modality, and it could provide the opportunity for easily accessible 3D postoperative feedback. Future studies are required to determine the reliability of this 3D concept with anteroposterior and lateral pelvic radiographs

and might be beneficial to ultimately guide intraoperative cup positioning.

## Appendix

**eA** An explanation of the trigonometric algorithm rationale and a table showing transverse version for given coronal inclinations and sagittal tilts are available with the online version of this article as a data supplement at <http://links.lww.com/JBJSOA/A50>. ■

NOTE: The authors are grateful to Professor R. Stevenson of the Korteweg-de Vries Institute for Mathematics, University of Amsterdam for due diligence regarding the mathematical algorithm.

T.E. Snijders, MD<sup>1</sup>  
T.P.C. Schlösser, MD, PhD<sup>1,2</sup>  
S.M. van Gaalen, MD, PhD<sup>1</sup>

R.M. Castelein, MD, PhD<sup>2</sup>  
H. Weinans, PhD<sup>2,3</sup>  
A. de Gast, MD, PhD<sup>1</sup>

<sup>1</sup>Department of Orthopaedics, Clinical Orthopedic Research Center – mN, Diaconessenhuis Zeist, Zeist, the Netherlands

<sup>2</sup>Department of Orthopaedics, UMC Utrecht, Utrecht, the Netherlands

<sup>3</sup>Department of Biomechanical Engineering, TU Delft, Delft, the Netherlands

E-mail address for T.E. Snijders: [tsnijders@diakhuis.nl](mailto:tsnijders@diakhuis.nl)

ORCID iD for T.E. Snijders: [0000-0001-5835-4619](https://orcid.org/0000-0001-5835-4619)

ORCID iD for T.P.C. Schlösser: [0000-0003-1517-5914](https://orcid.org/0000-0003-1517-5914)

ORCID iD for S.M. van Gaalen: [0000-0003-3470-6477](https://orcid.org/0000-0003-3470-6477)

ORCID iD for R.M. Castelein: [0000-0002-6182-0315](https://orcid.org/0000-0002-6182-0315)

ORCID iD for H. Weinans: [0000-0002-2275-6170](https://orcid.org/0000-0002-2275-6170)

ORCID iD for A. de Gast: [0000-0002-8923-7965](https://orcid.org/0000-0002-8923-7965)

## References

- Berry DJ, von Knoch M, Schleck CD, Harmsen WS. The cumulative long-term risk of dislocation after primary Charnley total hip arthroplasty. *J Bone Joint Surg Am*. 2004 Jan;86-A(1):9-14.
- Malkani AL, Ong KL, Lau E, Kurtz SM, Justice BJ, Manley MT. Early- and late-term dislocation risk after primary hip arthroplasty in the Medicare population. *J Arthroplasty*. 2010 Sep;25(6)(Suppl):21-5. Epub 2010 Jun 11.
- NSS Information and Intelligence. Scottish Arthroplasty Project, annual report 2017. 2017. <http://www.arthro.scot.nhs.uk/docs/2017/2017-08-08-SAP-Publication-Report.pdf?1>. Accessed 2017 Dec 22.
- American Joint Replacement Registry. American Joint Replacement Registry, annual report 2017. 2017. <http://connect.ajrr.net/2017-annual-report-download?hsCtaTracking=211910d3-f75a-440c-8bff-9d3da22c75ad%7C2cb33f5d-6e5a-405d-b3c6-dc5e1914c660>. Accessed 2017 Dec 30.
- Danoff JR, Bobman JT, Cunn G, Murtaugh T, Gorroochurn P, Geller JA, Macaulay W. Redefining the acetabular component safe zone for posterior approach total hip arthroplasty. *J Arthroplasty*. 2016 Feb;31(2):506-11. Epub 2015 Sep 18.
- Biedermann R, Tonin A, Krismer M, Rachbauer F, Eibl G, Stöckl B. Reducing the risk of dislocation after total hip arthroplasty: the effect of orientation of the acetabular component. *J Bone Joint Surg Br*. 2005 Jun;87(6):762-9.
- Lewinnek GE, Lewis JL, Tarr R, Compere CL, Zimmerman JR. Dislocations after total hip-replacement arthroplasties. *J Bone Joint Surg Am*. 1978 Mar;60(2):217-20.
- Pradhan R. Planar anteversion of the acetabular cup as determined from plain anteroposterior radiographs. *J Bone Joint Surg Br*. 1999 May;81(3):431-5.
- Pierchon F, Pasquier G, Cotten A, Fontaine C, Clarisse J, Duquenooy A. Causes of dislocation of total hip arthroplasty. CT study of component alignment. *J Bone Joint Surg Br*. 1994 Jan;76(1):45-8.
- Murray DW. The definition and measurement of acetabular orientation. *J Bone Joint Surg Br*. 1993 Mar;75(2):228-32.
- Snijders TE, Willemsen K, van Gaalen SM, Castelein RM, Weinans H, de Gast A. Lack of consensus on optimal acetabular cup orientation because of variation in assessment methods in total hip arthroplasty: a systematic review. *Hip Int*. 2018 May 01;1120700018759306. Epub 2018 May 1. Epub ahead of print.
- Equerra-Herrando L, Seral-García B, Quilez MP, Pérez MA, Albareda-Albareda J. Instability of total hip replacement: A clinical study and determination of its risk factors. *Rev Esp Cir Ortop Traumatol*. 2015 Jul-Aug;59(4):287-94. Epub 2015 Jan 28.
- Fujishiro T, Hiranaka T, Hashimoto S, Hayashi S, Kurosaka M, Kanno T, Masuda T. The effect of acetabular and femoral component version on dislocation in primary total hip arthroplasty. *Int Orthop*. 2016 Apr;40(4):697-702. Epub 2015 Jul 23.
- Jolles BM, Zangger P, Leyvraz PF. Factors predisposing to dislocation after primary total hip arthroplasty: a multivariate analysis. *J Arthroplasty*. 2002 Apr;17(3):282-8.
- McCullum DE, Gray WJ. Dislocation after total hip arthroplasty. Causes and prevention. *Clin Orthop Relat Res*. 1990 Dec;(261):159-70.
- Snijders TE, Schlösser T, van Gaalen S, Castelein RM, Weinans H, de Gast A. Non-equivalent results from different anteversion measurements methods for the evaluation of the acetabular cup orientation in total hip arthroplasty. Under review. *Orthop Surg*. 2017.
- McLawhorn AS, Sculco PK, Weeks KD, Nam D, Mayman DJ. Targeting a new safe zone: a step in the development of patient-specific component positioning for total hip arthroplasty. *Am J Orthop (Belle Mead NJ)*. 2015 Jun;44(6):270-6.
- Tannast M, Murphy SB, Langlotz F, Anderson SE, Siebenrock KA. Estimation of pelvic tilt on anteroposterior X-rays—a comparison of six parameters. *Skeletal Radiol*. 2006 Mar;35(3):149-55. Epub 2005 Dec 20.
- Renkawitz T, Weber M, Springorum HR, Sendtner E, Woerner M, Ulm K, Weber T, Grifka J. Impingement-free range of movement, acetabular component cover and early clinical results comparing 'femur-first' navigation and 'conventional' minimally invasive total hip arthroplasty: a randomised controlled trial. *Bone Joint J*. 2015 Jul;97-B(7):890-8.
- Sendtner E, Schuster T, Wörner M, Kalteis T, Grifka J, Renkawitz T. Accuracy of acetabular cup placement in computer-assisted, minimally-invasive THR in a lateral decubitus position. *Int Orthop*. 2011 Jun;35(6):809-15. Epub 2010 May 21.
- Yoon YS, Hodgson AJ, Tonetti J, Masri BA, Duncan CP. Resolving inconsistencies in defining the target orientation for the acetabular cup angles in total hip arthroplasty. *Clin Biomech (Bristol, Avon)*. 2008 Mar;23(3):253-9. Epub 2007 Dec 11.
- Gandhi R, Marchie A, Farrokhyar F, Mahomed N. Computer navigation in total hip replacement: a meta-analysis. *Int Orthop*. 2009 Jun;33(3):593-7. Epub 2008 Apr 3.
- Beckmann J, Stengel D, Tingart M, Götz J, Grifka J, Lüring C. Navigated cup implantation in hip arthroplasty. *Acta Orthop*. 2009 Oct;80(5):538-44.
- Reininga IHF, Zijlstra W, Wagenmakers R, Boerboom AL, Huijbers BP, Groothoff JW, Bulstra SK, Stevens M. Minimally invasive and computer-navigated total hip arthroplasty: a qualitative and systematic review of the literature. *BMC Musculoskelet Disord*. 2010 May 17;11:92.
- Moskal JT, Capps SG. Acetabular component positioning in total hip arthroplasty: an evidence-based analysis. *J Arthroplasty*. 2011 Dec;26(8):1432-7. Epub 2011 Feb 5.
- Xu K, Li YM, Zhang HF, Wang CG, Xu YQ, Li ZJ. Computer navigation in total hip arthroplasty: a meta-analysis of randomized controlled trials. *Int J Surg*. 2014;12(5):528-33. Epub 2014 Feb 27.
- Li YL, Jia J, Wu Q, Ning GZ, Wu QL, Feng SQ. Evidence-based computer-navigated total hip arthroplasty: an updated analysis of randomized controlled trials. *Eur J Orthop Surg Traumatol*. 2014 May;24(4):531-8. Epub 2013 Apr 16.
- Kanawade V, Dorr LD, Wan Z. Predictability of acetabular component angular change with postural shift from standing to sitting position. *J Bone Joint Surg Am*. 2014 Jun 18;96(12):978-86.
- Lembeck B, Mueller O, Reize P, Wuelker N. Pelvic tilt makes acetabular cup navigation inaccurate. *Acta Orthop*. 2005 Aug;76(4):517-23.
- Philippot R, Wegrzyn J, Farizon F, Fessy MH. Pelvic balance in sagittal and Lewinnek reference planes in the standing, supine and sitting positions. *Orthop Traumatol Surg Res*. 2009 Feb;95(1):70-6. Epub 2009 Jan 30.
- Tamura S, Takao M, Sakai T, Nishii T, Sugano N. Spinal factors influencing change in pelvic sagittal inclination from supine position to standing position in patients before total hip arthroplasty. *J Arthroplasty*. 2014 Dec;29(12):2294-7. Epub 2013 Dec 2.
- Kyo T, Nakahara I, Miki H. Factors predicting change in pelvic posterior tilt after THA. *Orthopedics*. 2013 Jun;36(6):e753-9.