

Clinical, mechanical, and immunohistopathological effects of tissue adhesives on the colon

An in-vivo study

Vakalopoulos, Konstantinos A.; Wu, Zhouqiao; Kroese, Leonard F.; van der Horst, Paul H.; Lam, King H.; Dodou, Dimitra; Jeekel, Johannes; Lange, Johan F.

DOI

[10.1002/jbm.b.33621](https://doi.org/10.1002/jbm.b.33621)

Publication date

2017

Document Version

Accepted author manuscript

Published in

Journal of Biomedical Materials Research. Part B: Applied Biomaterials

Citation (APA)

Vakalopoulos, K. A., Wu, Z., Kroese, L. F., van der Horst, P. H., Lam, K. H., Dodou, D., Jeekel, J., & Lange, J. F. (2017). Clinical, mechanical, and immunohistopathological effects of tissue adhesives on the colon: An in-vivo study. *Journal of Biomedical Materials Research. Part B: Applied Biomaterials*, 105(4), 846-854. <https://doi.org/10.1002/jbm.b.33621>

Important note

To cite this publication, please use the final published version (if applicable). Please check the document version above.

Copyright

Other than for strictly personal use, it is not permitted to download, forward or distribute the text or part of it, without the consent of the author(s) and/or copyright holder(s), unless the work is under an open content license such as Creative Commons.

Takedown policy

Please contact us and provide details if you believe this document breaches copyrights. We will remove access to the work immediately and investigate your claim.

Clinical, mechanical, and immunohistopathological effects of tissue adhesives on the colon: an in-vivo study

K. A. Vakalopoulos,¹ Z. Wu,¹ L. F. Kroese,¹ P. H. van der Horst,² K. H. Lam,³ D. Dodou,⁴ J. J. Jeekel,¹ J. F. Lange¹

¹Department of Surgery, Erasmus University Medical Center, Rotterdam, the Netherlands

²Department of Gynaecology and Obstetrics, Erasmus University Medical Center, Rotterdam, the Netherlands

³Department of Pathology, Erasmus Medical Center, Rotterdam, the Netherlands

⁴Department of Biomechanical Engineering, Delft University of Technology, Delft, the Netherlands

Vakalopoulos, K. A., Wu, Z., Kroese, L. F., van der Horst, P. H., Lam, K. H., Dodou, D., ... & Lange, J. F. (2017). Clinical, mechanical, and immunohistopathological effects of tissue adhesives on the colon: An in-vivo study. *Journal of Biomedical Materials Research Part B: Applied Biomaterials*, 105(4), 846-854. <https://doi.org/10.1002/jbm.b.33621>

ABSTRACT

Background: Tissue adhesives may be useful for sealing bowel anastomoses by preventing anastomotic leakage. Prior to clinical implementation, an in-depth analysis of the clinical and immunohistopathological effects of tissue adhesives on the target tissue and of the mechanical strength of the adhesive bond in an in vivo model is needed.

Materials and methods: In 84 rats, two bowel segments were glued using one of the following tissue adhesive: Bioglue, Gelatin-resorcinol-formaldehyde (GRF), Glubran 2, Histoacryl Flex, Omnex, Duraseal Xact, or Tissucol. Rats were followed for 7 or 28 days. Endpoints were clinical complication rate, mechanical strength, and immunohistopathological reactions.

Results: Of the seven tissue adhesives, GRF and Bioglue showed the highest rates of bowel wall destruction and ileus and the most severe immunohistopathological tissue reactions at 7 and 28 days. Cyanoacrylates (Histoacryl Flex, Omnex, Glubran 2) showed high mechanical strength and mild immunohistopathological reactions at 7 and 28 days. Duraseal Xact and Tissucol were the most inert tissue adhesives, but exhibited low mechanical strength. At 28 days, mechanical strength was significantly correlated to CD8, CD68, and Ki67 cell counts.

Conclusion: Based on the clinical and immunohistopathological outcomes, GRF and Bioglue were found to be the least suitable tissue adhesives for colonic use. Duraseal Xact and Tissucol were inert but also showed low mechanical strength. Cyanoacrylates exhibited mild clinical and immunohistopathological effects while maintaining high strength, which makes them promising as colonic sealants.

INTRODUCTION

In the field of gastrointestinal surgery, anastomotic leakage rates remain unacceptably high. This is especially true for the colorectal anastomosis, where leakage rates between 5% and 15% are still being reported, with subsequent mortality rates as high as 20%¹⁻⁴. The sealing of an anastomosis (i.e., the surgical connection of two bowel endings by staples or sutures) with a tissue adhesive (TA) has been a focus of surgical research during the past years⁵⁻⁷.

Present-day tissue adhesives (TAs) can be divided into four categories based on their chemical composition⁸. Cyanoacrylates (CA), the largest TA category, are known to form a rigid and watertight bond and have been recently proposed to be potential candidates for the sealing of bowel anastomoses^{5,9}. Fibrin glues (FGs) act as hemostats by enhancing the final stage of the clotting cascade and form a network of fibrin molecules with the adhesive substrate, and have been useful in the sealing of experimental colorectal anastomoses¹⁰⁻¹³. Polyethylene glycol adhesives (PEGs) are flexible hydrogels, primarily used in neurosurgery for sealing the Dura mater^{14,15}. Albumin-based (AB) adhesives, including gelatin-resorcinol-formaldehyde (GRF) adhesives, form a strong and flexible adhesive bond with the tissue and are used for the sealing of vascular anastomoses and in aortic

surgery^{16–18}. A disadvantage of GRF adhesive is that it contains formaldehyde, which has been linked to toxic effects on tissue^{6,11,19}.

In gastrointestinal surgery, FGs are used for staple line sealing after gastric bypass in bariatric surgery²⁰. Furthermore, recent research reported promising results for the sealing of the esophageal and the pancreaticoduodenal anastomosis with various TAs, including FG, CA, and PEG adhesives^{21–26}. Despite extensive experimental research in the field of colorectal surgery, anastomotic sealing with TAs has not yet been implemented into regular clinical practice. As previously described in the literature, this may be (at least partially) attributed to a lack of methodological consensus between experimental studies, inhibiting the comparison of available experimental data^{5,27,28}.

An in vitro study on the mechanical strength and the rheological properties of 12 clinically relevant TAs was recently performed by the authors⁸. The results showed that large differences exist between TAs in terms of mechanical strength, with CAs being the strongest TAs, followed by AB and PEG adhesives. FGs were mechanically the weakest among the tested TAs. Besides mechanical testing, evaluating the clinical and immunohistopathological effects of TAs on the target tissue is imperative prior to clinical implementation. Information on the immunohistopathological effects of TAs on bowel tissue remains scarce. In this study, a set of TAs from all four abovementioned adhesive categories were selected. Short- and long-term clinical effects, immunohistopathological effects, and the mechanical strength of the TA bond on colonic tissue were examined.

METHODS

This study was approved by the ethical committee on animal experimentation, under supervision of the Erasmus University Rotterdam (permit number 105–12-08). Eighty-four specified-pathogen-free male Wistar rats weighing 250–300 g were obtained from a licensed breeder (Charles River Laboratories, MA, USA). Rats were housed according to standard laboratory conditions, including individually ventilated cages with unrestricted access to standard rat chow and water. An acclimatization period of 1 week was observed. Rats were scored daily using a validated wellness score to assess the onset of peritonitis²⁹.

Tissue adhesives

Seven TAs were evaluated, as listed in Table 1. These TAs were chosen based on their mechanical and rheological profiles as derived from previous in vitro research from the authors, and had to be in use clinically⁸. In total, 12 rats were included per TA: 6 for short-term (7 days) and 6 for long-term (28 days) follow-up. Rat allocation was performed in a randomized manner by an independent researcher not otherwise involved in the experiment.

Table 1. Included tissue adhesives.

Group	Tissue adhesive	Composition	Manufacturer
1	Bioglue	Glutaraldehyde-albumin	Cryolife (Kennesaw, GA, USA)
2	GRF	Gelatin-resorcinol-formaldehyde	Microval (St. Juste Malmont, FR)
3	Histoacryl Flex	n-butyl-2-cyanoacrylate	B. Braun (Tuttingen, GER)
4	Omnex	2-octyl-cyanoacrylate and butyl lactoyl acrylate	Ethicon (J&J, Sommerville, NJ, USA)
5	Glubran 2	n-butyl-2-cyanoacrylate and methacryloxysulfolane	GEM S.r.l. (Viarregio, IT)
6	Duraseal Xact	Polyethylene Glycol, trylisine amine, N-hydroxy succinimide, blue dye	Covidien (Mansfield, MA, USA)
7	Tissucol	Fibrin glue with aprotinin	Baxter (Deerfield, IL, USA)

Surgical technique

Rats received analgesia (Rimadyl; 5 mg/kg subcutaneously) preoperatively and were anesthetized by isoflurane/oxygen inhalation. The abdomen was shaved and the skin was disinfected with ethanol 70%, after which the abdominal cavity was opened through a 3 cm midline incision. After identification of the cecum, a 1 cm antimesenteric segment of the proximal colon was mobilized and placed in direct contact with the serosal surface of the cecum and then fixed with two single serosal sutures (Dafilon 8–0, Ethicon, USA), one on each edge of the segment. In this manner, a 1 cm tension-free seroso-serosal bowel approximation, that is, the “proximal TA bond,” was created, on which the TA was applied. The surgical model is illustrated in Figure 1. Next, a distal segment of the ascending colon was mobilized and sutured to the descending colon in a tension-free manner following the abovementioned protocol, creating a second seroso-serosal approximation: the “distal

TA bond.” For each rat, 0.25 mL of TA was used per TA. Care was taken to prevent spillage of glue into the abdomen. Sufficient curing time was allowed, based on the manufacturers’ guidelines of each TA. The abdominal wall was closed in two layers using a continuous suture technique (Safil, 5-0. B. Braun, GER). A second dose of Rimadyl was administered 24 h postoperatively.

Clinical endpoints

At the end of the follow-up period, rats were anaesthetized, and the abdomen was opened using a U-shaped incision. The abdomen was macroscopically inspected for signs of bowel wall destruction, that is, the presence of abscess or fecal matter, ileus and adhesion formation. The tenacity of the adhesions was graded using the four-degree Zühlke classification, a universally accepted classification of adhesions based on surgical adhesiolysis (grade 0: no adhesions; grade 1: filmy adhesions, easily separated by blunt dissection; grade 2: stronger adhesions, separated by combination of blunt and sharp dissection; grade 3: strong adhesions, sharp dissection necessary; grade 4: very strong adhesions with organ attachment, sharp dissection with high risk of organ damage)³⁰.

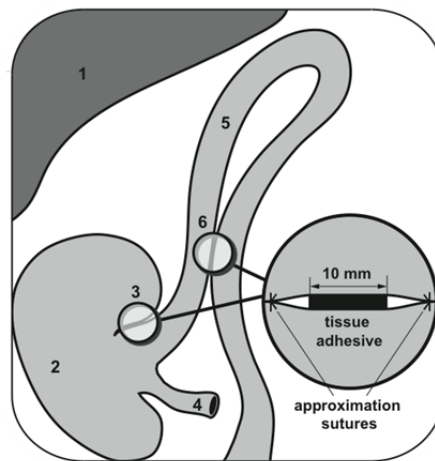


Figure 1. Surgical model. (1) Liver. (2) Cecum. (3) Proximal tissue adhesive bond. (4) Ileum (cut for the sake of clarity). (5) Colon. (6) Distal tissue-adhesive bond.

Immunohistopathological analysis

After assessing the clinical endpoints and prior to euthanization by cardiac puncture, the proximal TA site was resected and used for immunohistopathological analysis. All samples were fixed overnight in 4% paraformaldehyde, dehydrated using a graded ethanol series and xylene and subsequently embedded in paraffin, after which 5-mm-thick tissue sections from the paraffin blocks were cut. Automated hematoxylin and eosin (H&E) staining of the slides was performed using the MICROM slide stainer HMS 70 (MICROM International GmbH). Representative slides from each rat were used for immunohistochemical staining for CD4, CD8, CD20, CD68, and Ki67. Table 2 summarizes antibodies, manufacturers, and dilutions.

Table 2. Overview of antibodies used for immunohistochemical analysis.

Marker	Meaning of marker	Company	Dilution	Secondary antibody
CD4	Specific immuno response, expressed on T-helper lymphocytes	Emelca Bioscience, Breda, Netherlands	1:100	rabbit-anti-rabbit
CD8	Specific immuno response, expressed on cytotoxic ('Killer') T-lymphocytes	AbD Serotec, Kidlington, United Kingdom	1:200	rabbit-anti-mouse
CD20	Specific immuno response of B-cells, involved in antibody production	Emelca Bioscience, Breda, Netherlands	1:100	rabbit-anti-rabbit
CD68	Innate immuno response, expressed on macrophages	AbD Serotec, Kidlington, United Kingdom	1:1000	rabbit-anti-mouse
Ki-67	Cell-proliferation marker	Monosan, Uden, Netherlands	1:4000	rabbit-anti-rabbit

Scoring of Hematoxylin and eosin (H&E) and Ki-67

Upon staining, H&E slides were scored on inflammatory cell infiltration, fibroblast activity, neoangiogenesis, and collagen deposition using the Modified Phillips Scale³¹. In this scale, each of the histological parameters is scored from 0 to 4 as follows: 0 = no evidence; 1 = occasional evidence; 2 = light scattering; 3 = abundant evidence; and 4 = confluent cells or fibers. Furthermore, a general descriptive histological analysis was made per TA. For Ki-67, a cellular marker of proliferation, per rat the image field (10X enlarged) containing the highest concentration of cells was chosen, in which 10 fields were randomly chosen for scoring. Tissue at the TA/tissue interface was scored based on the amount of stained cells as part of the total cell population as: 1 = <5%, 2 = 5-25%, or 3 = >25%. H&E and Ki-67 scoring was performed during a single session in which four of the authors, including an experienced pathologist, evaluated each slide and provided their scores independently while blinded to the type of adhesive used. In case of discrepancies in scoring, slides were re-examined and discussed until consensus was reached.

Counting of the cells involved in the inflammatory response

After staining, slides were scanned with a slide scanner (Hamamatsu, Hamamatsu City, Japan). The TA–tissue interface was located on the computer screen and was enlarged 10 times (screen size 1024 X 768 pixels), after which five fields were randomly chosen for cell counting. The average cell count of the five fields was calculated for CD4, CD8, CD20, and CD68 using Image J software (National Institutes of Health, Bethesda, MD, USA).

Mechanical strength testing

The distal TA site was resected and, the two approximation sutures were cut without disturbing the TA bond. A custom made 4-mm-wide U-shaped pin was inserted intraluminally into each colonic segment, and then fixed in a tensile strength tester (Testometric, Rochdale, UK, type AX M250-2.5 kN). Tests were performed with a 20 N load cell, at a testing speed of 10 mm/min. No preload was applied. Computer-based analysis software was used to record force data as a function of time and the maximum tensile force was extracted from these data. All mechanical tests were performed directly after resection.

Statistical analysis

A Shapiro–Wilk test for normal distribution was performed prior to statistical analysis. Tensile strength data were normally distributed and compared between TA groups using one-way ANOVA and post-hoc Bonferroni multiple comparisons testing. Immunohistological data were non normally distributed and were compared between TA groups using the Kruskal–Wallis one-way analysis-of-variance test, followed by post-hoc Dunn’s multiple comparisons test. A *p* value of 0.05 or less was chosen to define statistical significance. All data analyses were performed using MATLAB (Version R2015a; The MathWorks, Inc, Natick, MA).

RESULTS

Clinical outcomes

A synopsis of clinical outcomes is provided in Table 3. At 7 days, macroscopic signs of fecal peritonitis, subsequent to bowel wall destruction at the distal TA site, were seen in two of the 42 rats, both in the GRF group. Furthermore, two cases of mechanical ileus were identified, both in the Bioglue group. GRF showed the largest number of adhesions as compared to the other six TAs. Histoacryl Flex also showed a large number of adhesions, mostly at the distal TA site and between other visceral structures. GRF and Omnex yielded the highest maximum Zühlke scores (i.e., tenacity of adhesions) for visceral and distal adhesions (GRF) and for adhesions to the proximal glue site (Omnex) when compared to the other TAs.

At 28 days, GRF had the highest complication rate, including one mortality at day 6, bowel wall destruction in two rats, and mechanical ileus in four rats. One rat in the Bioglue group was also found to have bowel wall destruction. All TAs showed numerous adhesions except for Duraseal Xact, which did not lead to any adhesions. As in the short-term group, GRF yielded the highest amount of adhesions and Zühlke scores.

Mechanical strength

Results of the tensile strength tests are summarized in Table 3. Shapiro–Wilk testing for normal distribution found that mechanical strength data was normally distributed (*p* = 0.07). One-way ANOVA testing showed significant differences in tensile strength between TAs at both 7 ($F(6,33) = 11.5, p < 0.001$) and 28 days ($F(6,32) = 28.1, p < 0.001$). At day 7, Histoacryl Flex was stronger than all other TAs (all *p* values < 0.003) except Bioglue (*p* = 0.855), whereas Tissucol exhibited the lowest tensile strength, significantly lower than Bioglue (*p* = 0.001) and Histoacryl Flex (*p* < 0.001).

At day 28, the strongest TA was GRF, which was statistically higher than all other TAs ($p < 0.01$), whereas the weakest TAs were Duraseal Xact and Tissucol, which both were significantly weaker than all other TAs ($p < 0.01$). There was no significant correlation between the tensile strength of the adhesives at day 7 and day 28. When excluding the tensile strength data of the sealant category, which were in an outlying lower range when compared to the other adhesives, a significant negative significant correlation between the tensile strength at day 7 and day 28 ($r = 20.44, p = 0.023$) was found.

Table 3. Synopsis of clinical outcomes.

	Tissue adhesive	Number of rats	Fecal peritonitis*	Mechanical Ileus*	Adhesions, Proximal**	Adhesions, Distal**	Adhesions to other viscera**	Max. Zuhlke score	Mean tensile strength (N (SD))
7 days	Bioglue	5***	0	2	2	4	2	3	1.05 (0.47)
	Histoacryl Flex	6	0	0	1	11	9	2	1.48 (0.46)
	GRF	6	2	0	4	16	13	4	0.38 (0.33)
	Duraseal Xact	6	0	0	0	2	0	0	0.39 (0.20)
	Glubran 2	6	0	0	0	4	0	0	0.64 (0.39)
	Tissucol	6	0	0	0	0	0	0	0.06 (0.07)
	Omnex	6	0	0	4	1	0	3	0.58 (0.24)
28 days	Bioglue	6	1	1	3	2	0	3	2.26 (1.12)
	Histoacryl Flex	6	0	0	5	7	0	2	1.83 (0.46)
	GRF	6	2	4	13	16	13	4	4.25 (1.29)
	Duraseal Xact	6	0	0	0	2	0	2	0.00 (0.00)
	Glubran 2	6	0	0	8	4	4	2	2.56 (0.24)
	Tissucol	6	0	0	8	1	0	2	0.07 (0.16)
	Omnex	6	0	0	6	5	0		1.80 (0.31)

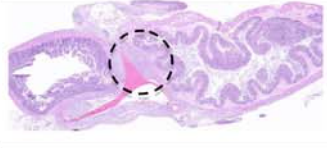


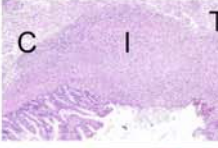

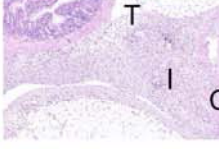


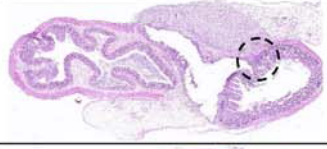
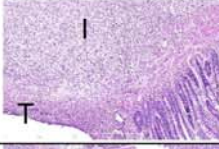
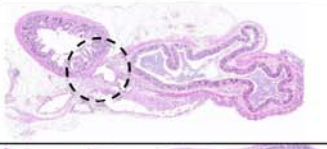
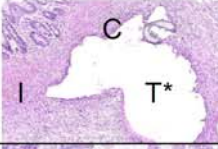
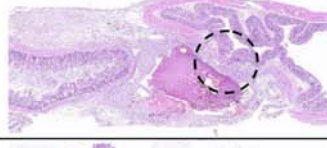
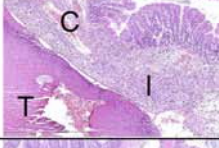

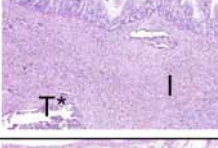
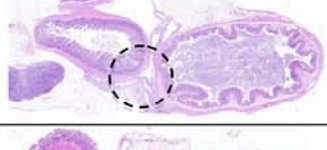

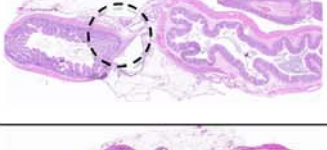
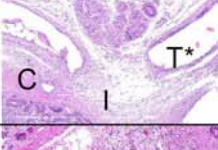
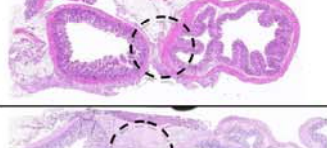
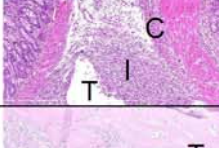
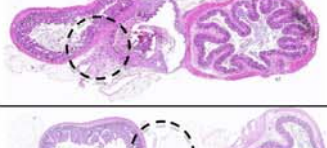





*Number of affected rats. **Amount of adhesions. ***One rat in this group died perioperatively following anaesthesia-related complications.

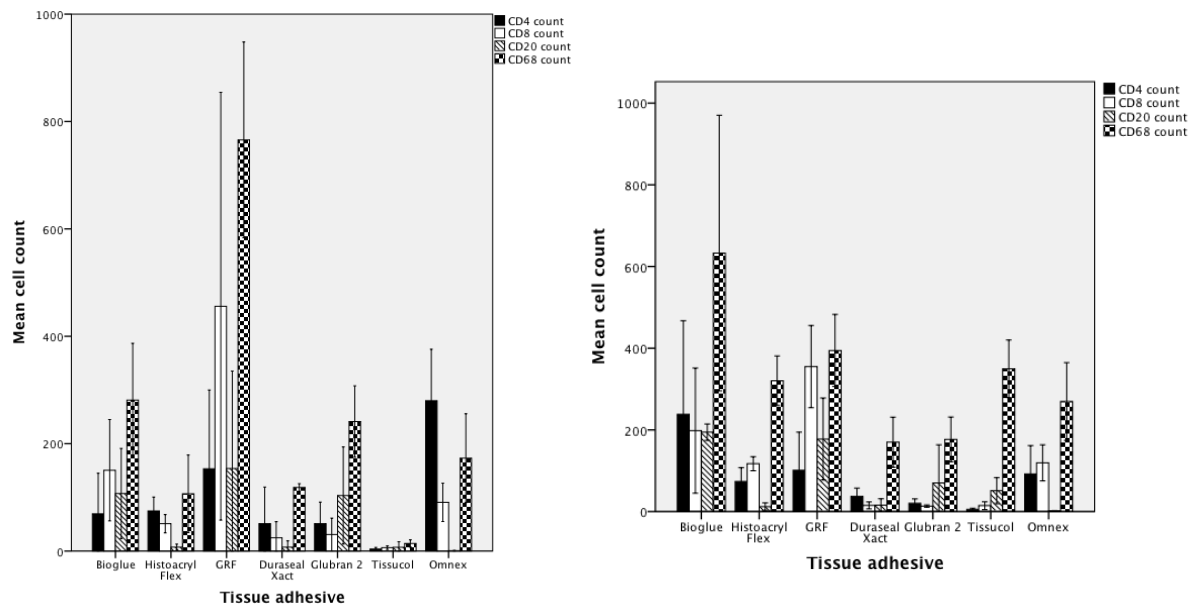
Histological and Immunohistochemical analysis

A descriptive summary of the histological results of each TA is provided in Table 4. An overview of the cell counts per immunological marker is provided in Figure 2(a,b) (at 7 and 28 days, respectively). At day 7, Ki-67, a marker of cell proliferation, was highest in Tissucol and lowest in the CAs Histoacryl Flex and Omnex, though no significant differences between TAs were found between groups ($F(6,33) = 11.1, p = 0.087$). At 28 days, GRF showed the highest Ki-67 count and Tissucol, Duraseal Xact and Omnex the lowest. At 28 days, significant differences were found between the seven TAs ($F(6,32) = 14.9, p = 0.021006$); however, no significant differences remained after post-hoc testing.

Kruskal–Wallis one-way analysis of variance testing revealed significant differences for all the remaining histopathological analyses at day 7 and day 28 ($p < 0.001$ in all cases). Results of post-hoc analyses by Dunn's multiple comparisons test are shown below. For CD4, a marker of T-helper cells, Bioglue and Histoacryl Flex showed the highest cell counts when compared to Tissucol at day 7 ($p = 0.004$ and $p = 0.037$, respectively). CD4 reaction at day 28 was highest in Omnex, significantly higher than in Tissucol ($p = 0.001$). CD8, a marker of cytotoxic T-cells, was found to be the highest for GRF at day 7, significantly higher than Duraseal Xact ($p = 0.004$), Glubran 2 ($p = 0.003$), and Tissucol ($p = 0.002$). At 28 days, GRF maintained the highest CD8 count, significantly higher than Tissucol ($p = 0.001$). For CD20, a marker of B-cell response, Bioglue and GRF showed the highest cell counts, both significantly higher than Omnex at 7 days ($p = 0.001$ and $p = 0.003$, respectively) and 28 days ($p = 0.01$ and $p = 0.004$, respectively). At 28 days, Glubran 2 also showed high CD20 counts, significantly higher than Omnex ($p = 0.023$). Lastly, CD68 score, a marker of macrophage response, was found to be the highest in Bioglue at day 7, significantly higher than Duraseal Xact ($p = 0.006$) and Glubran 2 ($p = 0.007$). At 28 days, it was GRF that showed the highest CD68 count, significantly higher than Duraseal Xact ($p = 0.015$) and Tissucol ($p < 0.001$). Glubran 2 and Bioglue were, in turn, both significantly higher than Tissucol ($p = 0.041$ and $p = 0.031$, respectively).

Table 4. Descriptive histopathological analysis. Illustrated per follow-up time point and amount of magnification. T:Tissue adhesive (*: Remnant) I: Inflammatory response. C: Collagen formation. **: Visible at higher magnification.

TA	7d. 1.25x	7d. 5x/10x	28d. 1.25x	28d. 5x/10x	Report
Bioglue					<p>7d: Acute inflammatory reaction to TA with peritonitis and muscle lysis, extending into the submucosal layer. Some giant cells are present**.</p> <p>28d: Deep bowel wall necrosis and leakage of bowel contents, causing a chronic inflammatory reaction.</p>
Duraseal					<p>7d: Local inflammatory reaction to TA remnants. Presence of plasma cells and neutrophils**. Degradation of TA evokes second stage inflammatory response. Inert TA.</p> <p>28d: Local inflammatory reaction, no signs of ongoing response. Limited macrophage/giant cell mediated foreign body reaction**.</p>
Glubran 2					<p>7d: Extended inflammatory response and local bowel wall necrosis, until the submucosal layer.</p> <p>28d: Extended inflammatory response and local bowel wall necrosis, until the submucosal layer.</p>
GRF					<p>7d: Acute inflammatory response with complete bowel wall necrosis. TA is scattered around the examined area.</p> <p>28d: Neutrophilic granulocyte acute response**. Large amounts of toxicity and macrophagic phagocytosis. Bowel wall necrosis until the lamina propria.</p>
Histoacryl Flex					<p>7d: Local inflammatory reaction to TA, no muscle lysis.</p> <p>28d: No inflammation or reaction to TA. Neovasculation present, indicating ongoing healing. Inert TA.</p>
Omnex					<p>7d: Limited local inflammatory reaction. A few inflammatory cells at TA. Inert TA.</p> <p>28d: Limited local inflammatory reaction. Few inflammatory cells at TA. Inert TA.</p>
Tissucol					<p>7d: Tendency of cell encapsulation into TA and subsequent scattering of TA. Very inert TA.</p> <p>28d: TA is completely dissolved. No ongoing reaction. Very inert TA.</p>



(a) (b)
Figure 2. Immunohistochemical analysis at (a) 7 and (b) 28 days.

Correlation analysis between tensile strength and immunohistochemistry

At 7 days, tensile strength correlated significantly only with CD4 ($r = 0.50$, $N = 7$, $p = 0.001$) and CD8 ($r = 0.39$, $N = 7$, $p = 0.014$) counts. At 28 days, tensile strength was significantly correlated to CD8 ($r = 0.48$, $N = 7$, $p = 0.003$), CD68 ($r = 0.68$, $N = 7$, $p = 0.001$), and Ki67 (Ranked transformed Spearman correlation; $r = 0.50$, $N = 7$, $p = 0.001$), indicating that high tensile strength was associated with a more severe response of CD4 and partly CD8 positive T-cells to the tissue adhesive. Correlation analysis between the short-term tensile strength and the long-term immunohistopathological outcomes of each tissue adhesive yielded no significant outcomes.

DISCUSSION

Sealing of colonic anastomoses with tissue adhesives (TAs) has been proposed as a promising new technique for preventing leakage of intraluminal contents through a (technically) insufficient anastomosis into the abdominal cavity. In this study, a comparative analysis of clinical, mechanical, and immunohistopathological endpoints of seven commercially available TA was performed, in a new experimental model that enables gluing two separate bowel segments per rat, while maintaining anatomical configuration and functionality during the follow-up period. By applying the TAs between two serosal surfaces without the presence of a bowel anastomosis, it was possible to observe the effects of the TA without confounding factors such as operative technique and anastomotic complications, thus providing a clear picture of the direct effects of the use of TA on the colon, information crucial to the understanding of the effectiveness and future clinical use of TAs in visceral surgery.

Clinical effects of TAs

Bioglue was associated with a higher rate of mechanical ileus (MI) compared to the other TAs, a finding which has previously been reported after use on mouse colonic anastomoses³². GRF use was associated with the only cases of bowel wall destruction and, subsequently, fecal peritonitis at day 7. Furthermore, at day 28, most complications were attributed to GRF use, which led to a higher incidence of mechanical ileus and bowel wall destruction than with the other TAs. These findings are in line with previous research on GRF, which reported toxicity after application of GRF on the bowel³². Of the seven TAs evaluated in this study, GRF showed the highest amount of adhesion formation. This finding may be explained by the severity of bowel wall destruction, mostly leading to fecal peritonitis and a subsequent strong inflammatory response, as seen in the immunohistochemical results. Histoacryl Flex showed more adhesion formation and higher tensile strength when compared to the other TAs at 7 days, while no differences remained at 28 days. This may indicate that the early adhesion formation seen in Histoacryl Flex depends on its strong adhesive bond to the surrounding tissue rather than collagen formation by the host, as was seen in the other TAs. The sealants Tissucol and Duraseal Xact showed the smallest amount of adhesions and the lowest complication rates at both 7 and 28 days, indicating safe use on the bowel surface. These findings are in line with previous research on the use of PEG adhesive³³.

Tensile strength

At both 7 and 28 days, CAs generally showed high tensile strength with a small standard deviation. The tissue sealants Duraseal Xact and Tissucol exhibited the lowest mechanical strength in this study. Duraseal Xact was completely dissolved at 28 days in all rats, resulting in a tensile strength of nil. FG also showed low tensile strength in this study, a finding that contradicts previous research in which sealing of rat colonic anastomosis with FG yielded high anastomotic bursting pressure¹², possibly due to the lack of a bowel defect and thus a TA bond directly on the serosal surface of the colon. In general, mechanical strength was higher at 28 days than at 7 days, indicating that the strength of a TA bond grows after initial application. GRF showed high tensile strength at 28 days, much higher than any other TA. This finding may be explained by extensive adhesion formation, as indicated by the high Zühlke scores that were observed with GRF. When comparing the *in vivo* results in this article to the *in vitro* results previously published by the authors⁸, it was found that *in vitro* mechanical strength was higher than the 7 days tensile strength measurements for all TAs and lower than the mechanical strength at 28 days. This finding infers that adhesive degradation may start sooner than expected after intracorporeal application.

Histopathology

Previous studies have primarily focused on the histopathology of FG and CA. Several authors reported promising effects of FG sealing of colonic rat anastomoses in which FG use led to only mild inflammatory reaction and no tissue toxicity^{10,12}. Regarding CA, early studies pointed out that long-chain CA formulations elicited an exothermic reaction leading to a severe inflammatory tissue response³⁴. However, present-day short-chain CA formulations have become more inert, indicating safe use intracorporeally^{35,36}. Information on the histological effects of the other TA categories on colonic tissue is scarce. A study by Yol et al. reported a higher infiltration of inflammatory cells, collagen, and fibroblasts for Bioglue applied on a rat colonic anastomosis compared to the use of platelet-rich plasma, a hydrogel which is thought to promote tissue healing³⁷.

In this study, Bioglue and GRF induced the most severe inflammatory reaction of all tested TAs. Of the CAs, Glubran 2 induced an extended inflammatory response with mild local muscle lysis as deep as the submucosal colonic layer. This finding was unexpected, as the chemical composition of Glubran 2 (n-butyl-2-cyanoacrylate/methacryloxysulfolane) does not differ considerably from either Histoacryl Flex (n-butyl-2-cyanoacrylate) or Omnex (n-octyl-cyanoacrylate/butyl lactoyl acrylate), which were both histologically inert. The mild toxic effects of Glubran 2 may possibly be attributed to methacryloxysulfolane, an additive in Glubran 2 that increases flexibility; this finding remains, however, unclear. Histoacryl Flex induced a limited local host reaction without tissue necrosis, with subsequent neoangiogenesis seen at day 28, indicating that this CA is relatively inert, without toxic effects on the bowel. The same can be stated for Omnex, which elicited a local and mild inflammatory response. The sealants, Duraseal Xact and Tissucol, were the most inert adhesives. Duraseal Xact caused a second inflammatory response after the initial degradation of the adhesive, which became apparent at day 28. This finding has not been observed in earlier research on PEG³⁸. This indicates that byproducts created through degradation of this TA elicit a more intensive tissue reaction than the response to the initial adhesive layer. This effect was, however, not clinically relevant as can be seen from the clinical and pathological evaluation. Tissucol showed an inflammatory response that was different to the other adhesives, with the body's host reaction encapsulating parts of the adhesive and cleaning these up rapidly before day 28, at which time Tissucol was almost completely dissolved. Note that in Tissucol, aprotinin is added to increase degradation time, meaning that in other FGs without aprotinin, the adhesive layer may dissolve even faster, possibly resulting in lower tensile strength.

Immunohistochemistry

This is the first study on TAs that implements the use of immunohistochemistry to aid in the understanding of the clinical and histological effects of TAs. CD4, CD8, and CD20 counts were evaluated, which indicate presence of T-helper cells, T-cytotoxic lymphocytes, and B-cells in the inflammatory response infiltrate, respectively. These cells play an important role in the response of the adaptive immune system of the host, and, more importantly in this study, in the regulation of the inflammatory response, which, in turn, affects the degradation of the TA. CD68 stains the macrophages, which have the double role of regulating the intensity of the inflammatory response as well as contributing in the healing process with the formation of collagen, an important contributor to long-term tensile strength. Lastly, Ki-67 indicates the rate of cell proliferation, which in this study is most likely linked to the intensity of wound healing or ongoing inflammatory reaction. When taking all parameters into account, it was found that the most severe inflammatory reaction was seen with Bioglue and GRF. At day 7, Bioglue showed the highest scores for CD4, CD20, and CD68, indicating that this TA was associated with the most intense short-term inflammatory response. This may be due to a direct toxic effect on the bowel surface, or to the initial degradation of the adhesive into toxic by-products. The large amount of CD4-positive T cells and CD68-positive macrophages indicate that there was a more intense inflammatory response

directed to this TA. The macrophages can, in turn, stimulate collagen formation, aiding in the high tensile strength found in Bioglue.

Interestingly, the number of CD20-positive B-cells was also found to be high in both Bioglue and GRF at day 7. These B-cells possibly also play a regulatory role in the inflammatory response. Moreover, there may be a relationship between allergic reactions of the host and these TAs involving the adaptive immune system, but this remains outside the scope of this article. The cell proliferation marker Ki67 was found to be the highest in Tissucol at 7 days. Taken together with its inert tissue reaction, this may indicate that physiological tissue healing may take place early on in the presence of this TA. At 28 days, GRF showed an ongoing (chronic) inflammatory response. This is confirmed by a high amount of CD4, CD8, CD20, and CD68. Also KI67 was highest in this TA, and points toward high cell proliferation as the result of the chronic inflammatory response. Omnex induced an isolated CD4 response higher than the other adhesives, also higher than that of the other CAs, a finding that remains unclear.

Study limitations and implications for future research

This study evaluated the effect of TA on intact bowel, without the presence of a defect, as would be the case after the creation of a bowel anastomosis. This aspect should be examined in future research. Moreover, the combination of TA use in the presence of a stapled colon anastomosis remains an interesting aspect for future research.

CONCLUSION

In this study, the use of a new experimental rat model was implemented for the comparative analysis of clinical effects, mechanical strength, and inflammatory response of a clinically relevant set of surgical tissue adhesives. Clinical complications were found only for GRF and Bioglue at both short- and long-term endpoints. Tensile strength analysis showed that the CA Histoacryl Flex was the strongest TA at 7 days, while GRF was the strongest at 28 days. Histopathological evaluation was in line with the clinical findings, with Bioglue and GRF eliciting the most severe inflammatory response and inducing bowel wall necrosis. Glubran 2 showed mild local muscle lysis in some cases while the other CAs and sealants were inert. The immunohistochemical findings correlated with TA tensile strength at 28 days. From this study, it seems that an optimal TA should elicit a minimal to moderate immune response to initiate high tensile strength without presence of an ongoing inflammatory response and subsequent clinical complications. These parameters were found in the included CAs, in particular in Histoacryl Flex and Omnex.

REFERENCES

1. Kingham TP, Pachter HL. Colonic anastomotic leak: risk factors, diagnosis, and treatment. *J Am Coll Surg.* 2009;208(2):269-78.
2. Wesselmann S, Winter A. Documented quality of care in certified colorectal cancer centers in Germany: German Cancer Society benchmarking report for 2013. *Int J Colorectal Dis.* 2014; Apr;29(4):511-8.
3. Komen N, Slieker J. High tie versus low tie in rectal surgery: comparison of anastomotic perfusion. *Int J Colorectal Dis.* 2011;26(8):1075-8.
4. Bruce J, Krukowski ZH. Systematic review of the definition and measurement of anastomotic leak after gastrointestinal surgery. *Br J Surg.* 2001;88(9):1157-68.
5. Vakalopoulos KA, Daams F. Tissue adhesives in gastrointestinal anastomosis: a systematic review. *J Surg Res.* 2013;180(2):290-300.
6. Reece TB, Maxey TS. A prospectus on tissue adhesives. *Am J Surg.* 2001;182(2 Suppl):40S-4S.
7. Bluestein D, Slepian MJ. Sticking with synthetic tissue sealants. *N Engl J Med.* 2014;370(16):1556-9.
8. Vakalopoulos KA, Wu Z. Mechanical Strength and Rheological Properties of Tissue Adhesives With Regard to Colorectal Anastomosis: An Ex vivo Study. *Ann Surg.* 2014; Feb;261(2):323-31.
9. Al-Mubarak L, Al-Haddab M. Cutaneous Wound Closure Materials: An Overview and Update. *J Cutan Aesthet Surg.* 2013;6(4):178-88.
10. Senol M, Altintas MM. The effect of fibrin glue on the intensity of colonic anastomosis in the presence and absence of peritonitis: an experimental randomized controlled trial on rats. *ISRN Surg.* 2013;2013:521413.
11. Spotnitz WD, Burks S. Hemostats, sealants, and adhesives II: Update as well as how and when to use the components of the surgical toolbox. *Clin Appl Thromb Hemost.* 2010;16(5):497-514.
12. Kanellos I, Mantzoros I. Effects of the use of fibrin glue around the colonic anastomosis of the rat. *Tech Coloproctol.* 2003; 7(2):82-4.
13. Van der Vijver RJ, van Laarhoven CJ. The effect of fibrin glue on the early healing phase of intestinal anastomoses in the rat. *Int J Colorectal Dis.* 2012;27(8):1101-7.

14. Kim KD, Wright NM. Polyethylene glycol hydrogel spinal sealant (DuraSeal Spinal Sealant) as an adjunct to sutured dural repair in the spine: results of a prospective, multicenter, randomized controlled study. *Spine (Phila Pa 1976)*. 2011;36(23):1906-12.
15. Neuman BJ, Radcliff K. Cauda equina syndrome after a TLIF resulting from postoperative expansion of a hydrogel dural sealant. *Clin Orthop Relat Res*. 2012; 470(6):1640-5.
16. Shiono M. Surgery for acute aortic dissection using gelatin-resorcin-formalin glue: perspective from 10 years of follow-up at a single center. *J Artif Organs*. 2008;11(1):19-23.
17. Fehrenbacher JW, Siderys H. Use of BioGlue in aortic surgery: proper application techniques and results in 92 patients. *Heart Surg Forum*. 2006;9(5):E794-9.
18. Vokri L, Qavdarbasha A. Experimental study of sutureless vascular anastomosis with use of glued prosthesis in rabbits. *Vasc Health Risk Manag*. 2015;11:211-7.
19. Witter K, Tonar Z. Tissue reaction to three different types of tissue glues in an experimental aorta dissection model: a quantitative approach. *Histochem Cell Biol*. 2010;133(2):241-59.
20. Fullum TM, Aluka KJ. Decreasing anastomotic and staple line leaks after laparoscopic Roux-en-Y gastric bypass. *Surg Endosc*. 2009;23(6):1403-8.
21. Upadhyaya VD, Gopal SC. Role of fibrin glue as a sealant to esophageal anastomosis in cases of congenital esophageal atresia with tracheoesophageal fistula. *World J Surg*. 2007;31(12):2412-5.
22. Saldana-Cortes JA, Larios-Arceo F. Role of fibrin glue in the prevention of cervical leakage and strictures after esophageal reconstruction of caustic injury. *World J Surg*. 2009;33(5):986-93.
23. Lillemo KD, Cameron JL. Does fibrin glue sealant decrease the rate of pancreatic fistula after pancreaticoduodenectomy? Results of a prospective randomized trial. *J Gastrointest Surg*. 2004;8(7):766-72.
24. Oida T, Mimastu K. Toward zero pancreatic leakage after pancreaticoduodenectomy for soft pancreas in low-volume pancreatic surgery centers. *Hepatogastroenterology*. 2009;56(91-92):886-90.
25. Yurtcu M, Arbag H. The healing effects of tissue glues and healing agent locally applied on esophageal anastomoses. *Int J Pediatr Otorhinolaryngol*. 2010;74(1):43-6.
26. Argyra E, Polymeneas G. Sutureless pancreatojejunal anastomosis using an absorbable sealant: evaluation in a pig model. *J Surg Res*. 2009;153(2):282-6.
27. Pommergaard HC, Achiam MP. External coating of colonic anastomoses: a systematic review. *Int J Colorectal Dis*. 2012;27(10):1247-58.
28. Cueto J, Barrientos T. Further Experimental Studies on a Biodegradable Adhesive for Protection of Colorectal Anastomosis. *Arch Med Res*. 2014 May;45(4):331-6.
29. Komen N, van der Wal HC. Colorectal anastomotic leakage: a new experimental model. *J Surg Res*. 2009;155(1):7-12.
30. Zuhlke HV, Lorenz EM. [Pathophysiology and classification of adhesions] Pathophysiologie und Klassifikation von Adhasionen. *Langenbecks Arch Chir Suppl II Verh Dtsch Ges Chir*. 1990:1009-16.
31. Kanellos D, Blouhos K. Effect of 5-fluorouracil plus interferon on the integrity of colonic anastomoses covering with fibrin glue. *World J Surg*. 2007;31(1):186-91.
32. Sliker JC, Vakalopoulos KA. Prevention of leakage by sealing colon anastomosis: experimental study in a mouse model. *J Surg Res*. 2013;184(2):819-24.
33. Sweeney T, Rayan S. Intestinal anastomoses detected with a photopolymerized hydrogel. *Surgery*. 2002;131(2):185-9.
34. Wu Z, Boersema GS. Critical analysis of cyanoacrylate in intestinal and colorectal anastomosis. *J Biomed Mater Res B Appl Biomater*. 2014;102(3):635-42.
35. Kanellos I, Mantzoros I. Sutureless colonic anastomosis in the rat: a randomized controlled study. *Tech Coloproctol*. 2002;6(3):143-6.
36. Elemen L, Sarimurat N. Is the use of cyanoacrylate in intestinal anastomosis a good and reliable alternative? *J Pediatr Surg*. 2009;44(3):581-6.
37. Yol S, Tekin A. Effects of platelet rich plasma on colonic anastomosis. *J Surg Res*. 2008;146(2):190-4.
38. Giuratrabocchetta S, Rinaldi M. Protection of intestinal anastomosis with biological glues: an experimental randomized controlled trial. *Tech Coloproctol*. 2011;15(2):153-8.