

Interstitial granulomatous dermatitis (IGD)

Tebeica, Tiberiu; Voicu, Cristiana; Patterson, James W.; Mangarov, Hristo; Lotti, Torello; Wollina, Uwe; Lotti, Jacopo; França, Katlein; Batashki, Atanas; Tchernev, Georgi

DOI

[10.3889/oamjms.2017.120](https://doi.org/10.3889/oamjms.2017.120)

Publication date

2017

Document Version

Final published version

Published in

Open Access Macedonian Journal of Medical Sciences

Citation (APA)

Tebeica, T., Voicu, C., Patterson, J. W., Mangarov, H., Lotti, T., Wollina, U., Lotti, J., França, K., Batashki, A., & Tchernev, G. (2017). Interstitial granulomatous dermatitis (IGD). *Open Access Macedonian Journal of Medical Sciences*, 5(4 Special Issue GlobalDermatology), 543-544.
<https://doi.org/10.3889/oamjms.2017.120>

Important note

To cite this publication, please use the final published version (if applicable).
Please check the document version above.

Copyright

Other than for strictly personal use, it is not permitted to download, forward or distribute the text or part of it, without the consent of the author(s) and/or copyright holder(s), unless the work is under an open content license such as Creative Commons.

Takedown policy

Please contact us and provide details if you believe this document breaches copyrights.
We will remove access to the work immediately and investigate your claim.

Interstitial Granulomatous Dermatitis (IGD)

Tiberiu Tebeica¹, Cristiana Voicu², James W. Patterson³, Hristo Mangarov⁴, Torello Lotti⁵, Uwe Wollina⁶, Jacopo Lotti⁷, Katlein França⁸, Atanas Batashki⁹, Georgi Tchernev^{10*}

¹Dr Leventer Centre, 13-17 Sevastopol Street, Ste. 204, Bucharest 010991, Romania; ²Dermatology Department, Polissano Clinic, 26Z Timisoara Blvd, Bucharest, Romania; ³Department of Pathology, University of Virginia Health System, 1215 Lee Street, Box 800214, Charlottesville, VA 22908, USA; ⁴Medical Institute of Ministry of Interior (MVR), Department of Dermatology and Dermatologic surgery, General Skobelev 79, Sofia, Bulgaria; ⁵Department of Dermatology, University of Rome "G. Marconi", Rome, Italy; ⁶Department of Biotechnology, Delft University of Technology, 2628 BC, Delft, The Netherlands; ⁷Department of Dermatology and Allergology, Academic Teaching Hospital Dresden-Friedrichstadt, Friedrichstrasse 41, 01067, Dresden, Germany; ⁸Department of Nuclear, Subnuclear and Radiation Physics, University of Rome "G. Marconi", Rome, Italy; ⁹Institute for Bioethics & Health Policy; Department of Dermatology & Cutaneous Surgery; Department of Psychiatry & Behavioral Sciences, University of Miami Miller School of Medicine - Miami, FL, USA; ¹⁰Abdominal and Thoracic Surgery, Department of Special Surgery, Medical University of Plovdiv, bul. "Peshtersko shose" Nr 66, 4000 Plovdiv, Bulgaria; *Department of Dermatology, Venereology and Dermatologic Surgery, Medical Institute of Ministry of Interior, and Onkoderma Polyclinic for Dermatology and Dermatologic Surgery, Sofia, Bulgaria

Abstract

Citation: Tebeica T, Voicu C, Patterson JW, Mangarov H, Lotti T, Wollina U, Lotti J, França K, Batashki A, Tchernev G. Interstitial Granulomatous Dermatitis (IGD). Open Access Maced J Med Sci. 2017 Jul 25; 5(4):543-544. <https://doi.org/10.3889/oamjms.2017.120>

Keywords: IGD; necrobiosis lipoidica; morphea like; prognostic value; plaque; target lesions.

***Correspondence:** Professor Dr Georgi Tchernev PhD, Chief of 1) Department of Dermatology, Venereology and Dermatologic Surgery, Medical Institute of Ministry of Interior (MVR), General Skobelev 79, 1606 Sofia; 2) Onkoderma- Polyclinic for Dermatology and Dermatologic Surgery, General Skobelev 26, Sofia, Bulgaria. GSM: 00359885588424. E-mail: georgi.tchernev@yahoo.de

Received: 02-Apr-2017; Revised: 11-Apr-2017; Accepted: 22-Apr-2017; Online first: 21-Jul-2017

Copyright: © 2017 Tiberiu Tebeica, Cristiana Voicu, James W. Patterson, Hristo Mangarov, Torello Lotti, Uwe Wollina, Jacopo Lotti, Katlein França, Atanas Batashki, Georgi Tchernev. This is an open-access article distributed under the terms of the Creative Commons Attribution-NonCommercial 4.0 International License (CC BY-NC 4.0).

Funding: This research did not receive any financial support.

Competing Interests: The authors have declared that no competing interests exist.

We report the case of a 42 years old male patient suffering from skin changes, which appeared in the last 7-8 years. Two biopsies were performed during the evolution of the lesion. Both showed similar findings that consisted in a busy dermis with interstitial, superficial and deep infiltrates of lymphocytes and histiocytes dispersed among collagen bundles, with variable numbers of neutrophils scattered throughout. Some histiocytes were clustered in poorly formed granuloma that included rare giant cells, with discrete Palisades and piecemeal collagen degeneration, but without mucin deposition or frank necrobiosis of collagen. The clinical and histologic findings were supportive for interstitial granulomatous dermatitis. Interstitial granulomatous dermatitis (IGD) is a poorly understood entity that was regarded by many as belonging to the same spectrum of disease or even synonym with palisaded and neutrophilic granulomatous dermatitis (PNGD). Although IGD and PNGD were usually related to connective tissue disease, mostly rheumatoid arthritis, some patients with typical histologic findings of IGD never develop autoimmune disorders, but they have different underlying conditions, such as metabolic diseases, lymphoproliferative disorders or other malignant tumours. These observations indicate that IGD and PNGD are different disorders with similar manifestations.

We report the case of a 42 years old male patient suffering from skin changes as presented in Fig. 1, which appeared in the last 7-8 years. The physical examination revealed the presence of a large, round, brownish plaque with whitish atrophic dotted areas on its surface, of 8x6 cm, with well-defined margins, located on the posteroinferior region of his left arm. His medical history was positive for insulin dependent diabetes mellitus with an episode of ketoacidosis in the past, chronic pancreatitis, cholelithiasis, chronic antrum gastritis with negative *Helicobacter Pylori* tests. The patient's blood

profile, including routine tests, CRP, C3, C4, *Borrelia Burgdorferi* IgG and IgM, Quantiferon, Ac anti-HBC, Ag Hbs were all within normal levels.

Two biopsies were performed during the evolution of the lesion (in 2012 and 2017 respectively). Both showed similar findings that consisted in a busy dermis with interstitial, superficial and deep infiltrates of lymphocytes and histiocytes dispersed among collagen bundles, with variable numbers of neutrophils scattered throughout (Fig. 2). Some histiocytes were clustered in poorly formed granuloma that included rare giant cells, with discrete

Palisades and piecemeal collagen degeneration, but without mucin deposition or frank necrobiosis of collagen. The clinical and histologic findings were supportive for interstitial granulomatous dermatitis.

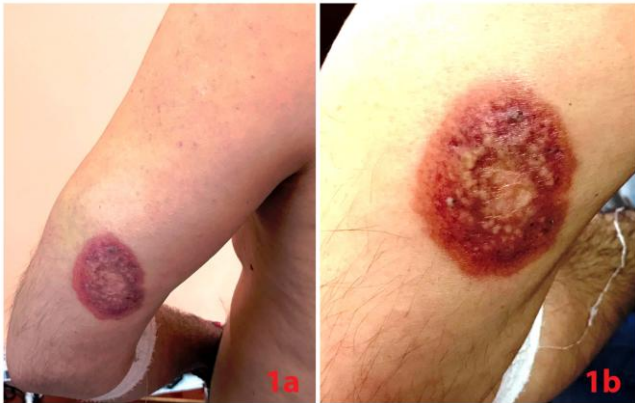

Figure 1: Clinical aspect. a: Large erythematous plaque with dotted whitish areas on the surface; b: Close-up view

Interstitial granulomatous dermatitis (IGD) is a poorly understood entity that was regarded by many as belonging to the same spectrum of disease or even synonym with palisaded and neutrophilic granulomatous dermatitis (PNGD). Although IGD and PNGD were usually related to connective tissue disease, mostly rheumatoid arthritis [1], some patients with typical histologic findings of IGD never develop autoimmune disorders, but they have different underlying conditions, such as metabolic diseases, lymphoproliferative disorders or other malignant tumours. These observations indicate that IGD and PNGD are different disorders with similar manifestations [2].

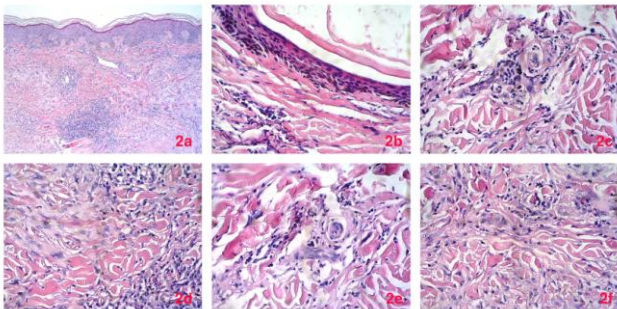


Figure 2: Microscopic features of the cutaneous lesion. 2a) Low power view showing interstitial granulomatous infiltrate, with patchy lymphocytes and vasodilatation; 2b) interstitial inflammation adjacent to a dilated follicle; 2c) interstitial granulomatous infiltrate with a few neutrophils; 2d) higher power view of the interstitial granulomatous infiltrate; 2e) interstitial granulomas with scattered neutrophils – note that mucin deposition is not a prominent feature; 2f) "piecemeal" degeneration of cross-sectional profiles of collagen bundles can be seen along the top of this figure – collagen bundles are surrounded by cleft-like spaces and small macrophages.

From the clinical point of view, the lesions in IGD may be variable: linear rope-like, papular, and even large plaques located on the extensor surface of the extremities [3]. Our main differential diagnosis was necrobiosis lipoidica, usually seen in the context of

diabetes mellitus. Although there was a history of diabetes, both biopsies in our case showed no prominent foci of collagen degeneration, and no layering of the histiocytic infiltrate to support this diagnosis.

Other entities that may be brought into discussion when an interstitial granulomatous pattern is encountered microscopically are interstitial granuloma annulare, histiocytoid Sweet syndrome and interstitial drug eruptions, but they could be reliably excluded on clinical basis.

The clinical case presented above shows the complex nature of IGD and its occurrence in non-rheumatologic setting. The presence of an interstitial granulomatous pattern of inflammation in biopsies from patients with systemic disease requires careful attention. The observer should not be sidetracked by the classic association of diabetes with necrobiosis lipoidica and overcall it. Similarly, it is to be kept in mind that IGD may not be necessarily associated with arthritis.

References

1. Sanguenza OP, Caudell MD, Mengesha YM, Davis LS, Barnes CJ, Griffin JE, Fleischer AB, Jorizzo JL. Palisaded neutrophilic granulomatous dermatitis in rheumatoid arthritis. *J Am Acad Dermatol.* 2002;47(2):251-7. <https://doi.org/10.1067/mjd.2002.124620> PMID:12140472
2. Peroni A, Colato C, Schena D, Gisondi P, Girolomoni G. Interstitial granulomatous dermatitis: a distinct entity with characteristic histological and clinical pattern. *Br J Dermatol.* 2012;166(4):775-83. <https://doi.org/10.1111/j.1365-2133.2011.10727.x> PMID:22059717
3. Tomasini C, Pippione M. Interstitial granulomatous dermatitis with plaques. *J Am Acad Dermatol.* 2002;46(6):892-9. <https://doi.org/10.1067/mjd.2002.120532> PMID:12063487