

Breast Cancer Detection

The Development and Pilot Study of a “Tactile Landscape” as a Standardized Testing Tool

Veitch, Daisy E.; Bochner, Melissa; Molenbroek, Johan F.M.; Goossens, Richard H.M.; Owen, Harry

DOI

[10.1097/SIH.0000000000000365](https://doi.org/10.1097/SIH.0000000000000365)

Publication date

2019

Document Version

Final published version

Published in

Simulation in Healthcare

Citation (APA)

Veitch, D. E., Bochner, M., Molenbroek, J. F. M., Goossens, R. H. M., & Owen, H. (2019). Breast Cancer Detection: The Development and Pilot Study of a “Tactile Landscape” as a Standardized Testing Tool. *Simulation in Healthcare, 14*(3), 201-207. <https://doi.org/10.1097/SIH.0000000000000365>

Important note

To cite this publication, please use the final published version (if applicable). Please check the document version above.

Copyright

Other than for strictly personal use, it is not permitted to download, forward or distribute the text or part of it, without the consent of the author(s) and/or copyright holder(s), unless the work is under an open content license such as Creative Commons.

Takedown policy

Please contact us and provide details if you believe this document breaches copyrights. We will remove access to the work immediately and investigate your claim.

Breast Cancer Detection

The Development and Pilot Study of a “Tactile Landscape” as a Standardized Testing Tool

Daisy E. Veitch, PhD Candidate;

Melissa Bochner, MB, BS, MS,
FRACS;

Johan F. M. Molenbroek, MSc, PhD;

Richard H. M. Goossens, MSc, PhD;

Harry Owen, MD, FRCA, FANZCA,
MB ChB

Introduction: There is still a need for competent breast lump detection palpation skills, especially in developing countries. Our goal is to design, develop, and establish a test to determine whether students can, by touch alone, identify and discriminate between a range of different simulated lesions at different adiposity levels.

Methods: Common lesions, breast cancers, and cysts were physically simulated and hidden in a test object referred to as the “tactile landscape” (TL). Ribs, intercostal muscle, and nodularity—normal anatomical features—increased their realistic complexity. Varying depths of features simulated varying degrees of adiposity. A testing protocol was created to determine the testee's ability to *identify* and *discriminate* different commonly occurring breast masses using palpation. Five experts (four breast surgeons and one general practitioner) and 20 inexperienced medical students were recruited and tested. Results were compared.

Results: The TL has been based on previously verified breast models and has softness similar to 53% of women's breasts and nodularity similar to 60% as assessed in a breast clinic by breast surgeons. The five experts indicated that the simulated lesions felt like those they might encounter in clinical practice and all of them identified the lesions and nonlesions hidden in the TL 100% correctly, thus indicating the value of the model. In contrast, only one student was able to identify all the lesions. One student identified none of them. The remaining students mean score was 65%.

Conclusions: All students but one performed poorly in comparison to the experts. This indicates that the test could be useful to test students' ability to identify and discriminate breast masses. If successful, it will add previously missing capability to the mix of assessment instruments already used, thus potentially improving clinical breast examination training and assessment.

(*Sim Healthcare* 14:201–207, 2019)

Key Words: Simulation, clinical breast examination, testing, training, breast cancer.

“To ignore lump detection as part of our construct of breast examination is as remiss as leaving out reading comprehension from a test of reading ability.”¹

“Breast cancer was the most common cancer in women worldwide, contributing 25.4% of the total number of new cases diagnosed in 2018.”²

The “criterion standard” for diagnosis of breast cancer is the Triple Test of clinical breast examination (CBE), imaging,

and biopsy, which combined have a 99.4% accuracy for detecting malignancy.³ The accuracy is so high because each of the components of the Triple Test can detect cancers missed by the others. A proportion of breast cancers (9.8%) are not revealed through mammography with 6.8% of these cancers being found through CBE.^{3,4} This underrecognized fact combined with loss of CBE skills is a major reason for physician-caused delay in the diagnosis of breast cancer⁵; therefore, CBE is still relevant and important. The identification and discrimination of breast masses (IDBM) through CBE make it a core clinical skill for many medical practitioners.

Standardization of CBE has been reported to improve sensitivity in lump detection^{6–8} and an evidence-based recommended technique has been published by Goodson.⁵ However, there has been no agreement on standardization of CBE and trainees are exposed to differing techniques.⁹ In addition to IDBM through CBE, the learner should demonstrate that their technique can be modified to accommodate variation such as large breasts and normal variation in nodularity in breasts. However, current testing for IDBM proficiency does not test for these skills. As with other clinical skills, simulation can be a valuable tool for teaching and assessing CBE.

Dilaveri et al¹⁰ (2013) in a systematic review and meta-analysis of simulation training for breast and pelvic physical examination identifies core skills as obtaining the clinical

From the Faculty of Industrial Design Engineering (D.E.V.), Delft University of Technology (TU Delft), Delft, the Netherlands; Breast Endocrine and Surgical Oncology Unit (M.B.), Royal Adelaide Hospital, Adelaide, SA, Australia; Faculty of Industrial Design Engineering (J.F.M.M., R.H.M.G.), Delft University of Technology (TU Delft), Delft, the Netherlands; and College of Medicine and Public Health (H.O.), Flinders University, Adelaide, SA, Australia.

Reprints: Daisy Ellen Veitch, PhD Candidate, 102 Gloucester Avenue, Belair, 5052, South Australia, Australia (e-mail: daisy@sharpdummies.com.au; daisy.veitch@gmail.com).

The authors declare no conflict of interest.

Supplemental digital content is available for this article. Direct URL citations appear in the printed text and are provided in the HTML and PDF versions of this article on the journal's Web site (www.simulationinhealthcare.com).

Copyright © 2019 The Author(s). Published by Wolters Kluwer Health, Inc. on behalf of the Society for Simulation in Healthcare. This is an open-access article distributed under the terms of the Creative Commons Attribution-Non Commercial-No Derivatives License 4.0 (CCBY-NC-ND), where it is permissible to download and share the work provided it is properly cited. The work cannot be changed in any way or used commercially without permission from the journal.

DOI: 10.1097/SIH.0000000000000365

history (simulated), performing the examination on a model including inspection and palpation, and identifying and describing lesions. Proficiency in breast examination is defined as performing a complete examination, identifying all existing lesions, and describing the location and character of each lesion without error.¹¹ There are two main problems with the current system. Firstly, “Skills were typically tested with the same simulator model used for training,”¹⁰ meaning that students can learn for the specific assessment instead of acquiring the IDBM CBE skills required for clinical success. Secondly, current simulator models such as Mammacare are anatomically simplistic, lacking ribs, nodularity, and human variation and simulate a small-breasted patient, making the identification of masses easier and less complex on a model than a real patient.

We have developed and validated more realistic models for teaching breast examination; this has previously been described.¹² We wished to test our simulation models against other models and teaching techniques, including low and high fidelity models, to determine whether students would have more efficient and effective learning in the specific skill of IDBM in a way that simulated some of the findings they might encounter in a clinical situation. However, given that students trained on a specific model would have an advantage when tested if they were examined using the same model they trained on, we needed a stand-alone physical test to test IDBM as a stand-alone physical skill. This would allow the fairer testing of different teaching styles.

These gaps led us to develop a simulation model we have called the tactile landscape (TL), which incorporates the feel of normal anatomical structures as well as various breast lesions.

The use of the TL would improve the consistency of assessment of CBE, improve the realism of skills required for IDBM during CBE, highlight effective teaching methods, and identify those students and trainees who need greater support to gain proficiency in the skill of IDBM in CBE.

AIM

Our goal is to design, develop, and establish a test to determine whether students can, by touch alone, identify and discriminate between a range of different simulated lesions at different adiposity levels. In this article, our aim is specifically to determine whether a test can be developed that can effectively distinguish between skill levels for IDBM during CBE testing and remediation.

METHODS

Ethics Approval

Ethics approval was obtained from Southern Adelaide Clinical Human Research Ethics Committee Number 34.13.

Development of the TL—A New Breast Simulator

What Is the TL?

A wooden tray containing strata of silicone layered upon a sloping wooden ribbed base designed to reconstruct the topography of the natural range of breast anatomy and adiposity above a base representing the ribcage.

Materials

The materials chosen were selected after rigorous testing, as described by Veitch et al (2018).¹² They were predominately

plywood, medium-density fibreboard, and silicones of differing shore values: all components are itemized with some specifications in Table 1.

Assembly

Assembly was as follows: the tray base was constructed, the ribs cut and nailed, the intercostal material poured and allowed to set, 200 mL of “fat” was poured in the deep end to elevate the components, the components of fibroglandular tissue, cysts and cancers were placed on the base and glued, the tray photographed to record location of components, remaining fat poured and allowed to set, skin poured and allowed to set, and skin painted, dried, and then powdered.

Design Rationale

Why did we flatten the breast? This minimizes its thickness and thereby allows us to more easily and more accurately examine it. The TL appears flat but is only relatively flattened, ie, displaced superiorly and laterally to represent breast movement from the upright position to the supine. This is in keeping with the real breast where the subject is supine and their breast is displaced this way during CBE. The large amount of breast movement is shown in a magnetic resonance imaging of the same patient prone and supine in Veitch et al (2018).¹² The breast moves both superiorly and laterally during the torso movement from upright to supine.¹³

Why did we slope the internal rib cage? Each breast although relatively flattened still has thickness variations. In addition, different cup sizes (A through to E and above) have different amounts of tissue. Variations in adiposity change the feel of the breast. We have sloped the contour of the ribcage to allow the student to experience the changed feeling caused by different amounts of adiposity. The shallow end labeled “A” represents ribs to skin difference of 25 mm and the deep end labeled “E” creates a 55-mm difference.

The TL was developed using an iterative design process. Prototypes were examined by a breast surgeon for tactility, look, and feel, and the feedback received was used to make increasingly realistic TLs. The design method used here is similar to that described by Veitch et al (2018)¹² and parts of the TL are exactly the same as those used to make the realistic breast models. In particular, the selection of materials, the development of the layering, and the components, lessons learned were all directly applicable and used in the building of the TL. The lead author is a model maker and made the TL herself, the second author is a breast surgeon with a 22-year experience, and the last author is an expert in medical simulation, so the design team was very strong.

The TL frame is marked with the numbers 1 to 5 along the short edge and A to F along the long edge, with A being at the shallow end and F the deep end, to simulate breast cup sizes. This allows a unique grid location code for each object to be created that facilitates identifying the precise locations of lesions during the testing process.

The TL has the following three varying features: (1) breast lesions, (2) normal anatomical features, and (3) attention to body mass index. The lesions were two types of commonly occurring pathology: (1) cancers; see Fig. 1: see coordinates (A,1), (A,2), (B,1), (B,2), (C,4), and (E,3); and (2) cysts; see Figure 1: (B,4), (B,5), (E,1), and (F,5); and a calibration object (A,3)

TABLE 1. Tactile Landscape Component Descriptors

Anatomical Feature	Material Used for Simulation	Shape or Position	Hardness	Size
Tray base	Wood	Rectilinear – 12-mm plywood	Not applicable – rigid	305 × 475 × 75 mm
Ribs	Wood	Medium density fiberboard of a flat quad profile placed diagonally 45 degrees of the rib protuberance	Not applicable – rigid	25-mm strips spaced 25 mm apart
Intercostal	Silicone	Liquid poured to just below the maximum height of the rib protuberance	Shore 10A	200 mL
Fibroglandular tissue	Silicone	Shape created from magnetic resonance imaging data	Shore 00–10	Various
Cancers	Silicone	From a mold	Shore 00–10	10 mL
Cysts	Two types of silicone	Shell created around various diameter beads, 25 mm and set then injected with the fat silicone	Surround shore 10A filled with silicone shore value <00	10 g surround then filled using a syringe
Calibration object	Glass	Hemisphere	Not applicable – rigid	10-mm-diameter base
Fat	Silicone gel	Liquid	Not applicable – softer than Shore 00	3500 m
Skin	Silicone	Liquid	Shore 00–10	100 mL plus 6 g of silicone oil (thinner)
Paint	Platinum silicone paint	Creates the look of skin		
Surround	Plastic 90-degree angle edging with mitered corners	Grid reference to provide coordinates (1, 2, 3, 4, and 5 on short edge and A, B, C, D, E, and F on the long edge)		
Powder	Creating silky skin feel	Any type of face powder or makeup finish Applied with a makeup brush		
Warmth		TL warmed before use with a hot water bottle		

to orient the student. Before commencing, we used a 10-mm-diameter glass marble halved with the dome face up to make sure that they can feel this object at (A,3). The normal anatomical features were ribs (Fig. 1: white 45-degree diagonal lines), intercostal muscle (Fig. 1: flesh-tone 45-degree diagonal lines), and breast nodularity (Fig.1: (C,1), (C,2), (C,3), (D,1), (D,2), (D,3)). These features increased the complexity and realism of the TL. Varying degrees of adiposity were simulated by varying the depths of the lesions and anatomical features using a tray with a sloped base that went from shallow to deep as shown on the lower portion of Figure 1.

All objects were visually hidden in a test object, covered by simulated fat and a layer of skin that was then painted with veins, etc. for visual realism (see the upper section of Figure 1). In addition, the TL was warmed with hot water bottles and lightly powdered to create a dry silky feel similar to skin, before the examinations. This detail enhances the cross-modal links in attention between touch and vision (Spence 2002), making the experience more realistic.

Assessment of the TL

A testing and marking protocol was developed to determine the degree of skill the testee has in the IDBM by touch alone (see document, Supplementary Digital Content 1, <http://links.lww.com/SIH/A416>, TL assessment tool). Both experts and students followed the same testing protocol.

Students' Background

Twenty students in their final undergraduate year volunteered before admission into a 4-year postgraduate Doctor of Medicine degree; thus, they had no clinical experience. They were chosen because they were novices without experience, and thus, we avoided other possibly confounding factors such as previous training and experience. This was confirmed by an entry questionnaire asking specifically about previous breast examination experience. There were also time and space constraints: the students were proctored by breast nurses who normally work in a breast clinic, and in the time available, we could only test 20 students. They were 10 female and 10 male students whose average age was 20.75 years.

Training

The students received 30 minutes of training in CBE before being tested with TL. This is the same training usually given to 2nd-year postgraduate medical students who have some clinical examination experience. The students were trained in two groups simultaneously by two expert clinicians, both breast surgeons from Royal Adelaide Hospital, each with 22 years of clinical experience. The 30 minutes of teaching involved a short theory introduction outlining the examination and symptoms of disease, followed by a practical session of 20 minutes where there was a demonstration on a standardized patient and each student had hands-on practice.

Experts' Background (n = 5)

There were five medical experts recruited and given the TL test. Of these, four were breast surgeons, two having practiced 22 years, one 20 years (10 years as a general practitioner, 10 as a breast surgeon), and one a trainee breast surgeon. There was also a general practitioner with 37 years of experience in general practice.

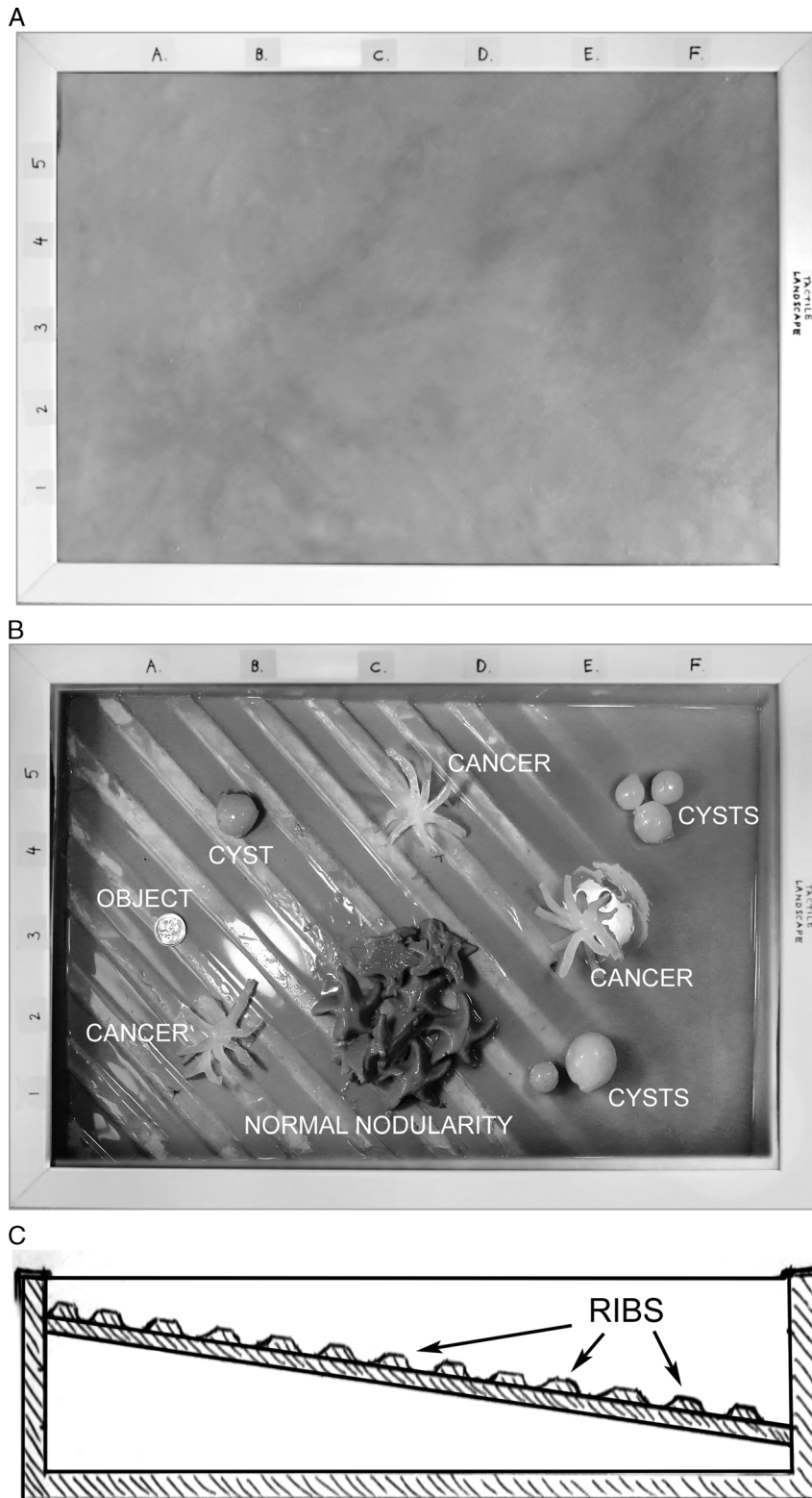


FIGURE 1. A, Tactile landscape presented as a test object with all objects hidden. The skin has been painted to look like skin. B, Tactile landscape with objects positioned ready to be covered by silicone simulating fat and skin. C, cross-sectional diagram showing deep and shallow ends to simulate large and small breasts.

Testing

The experts were not time restrained, but the time they took to complete the task was recorded, and students were then allocated more time than the slowest expert

(7–9 minutes). The novice medical student participants were given 30 minutes of CBE training and then given 11 minutes to examine the TL, starting with being guided to the calibration object in sector (A,3). They were asked to thoroughly examine

the TL and sketch the location of any breast masses on a diagram marked with a corresponding grid to the TL (see Supplementary Digital Content 1). They were asked to describe each mass they found and record whether they found the mass suspicious and, if so, what action would they take?

There were two identical TL, and we ran two assessments simultaneously. Each student was proctored by an experienced breast nurse. The two breast nurses both have more than 10 years of experience working in a women's health clinic in a major teaching hospital in South Australia. Nurses were coached by the breast surgeon to standardize the proctoring. The nurse introduced the student to the TL and explained the task of identifying and discriminating any "breast masses," which the student was required to record along with its location coordinates. The student was guided to the calibration object. The nurse then observed the student for 11 minutes using the same marking criteria for all students. The nurse noted whether the student examined all areas of the TL and seemed to use appropriate hand technique and appropriate pressure and marked them on a six-point scale with 0 indicating "not at all" and 5 indicating "always." The breast nurses could also write additional comments like "The student carried out the examination with a pen in their hand."

The answer sheets were marked and the testee was given a score of 6 for the six possible lesions they could have found. Any identified lesions are true positives, missed lesions are false negatives, and any "ghost" lesions are false positives.

RESULTS

The TL

The TL was extensively tested for lifelike feel during development—the TL uses identical materials and construction as the breast models described in a previous article (Veitch et al¹²). Each breast model described in Veitch et al.¹² differs in feel from the other models, and together, they represent a range of normal as do real patients. Thus, each breast model is similar only to a subgroup in the range of normal. The TL feels most similar to breast models 2 and 4 from the developed set. Upon examination of 78 breast patients (n = 78) in a regular breast clinic, breast models 4 and 2 were found to be similar to 60% of the patients for nodularity and 53% of patients for durity.¹² Thus, the TL, though not representing everyone,

is similar to more than 50% of patients. The TL is in the middle of the distribution of normal variation for breast hardness (durity), and there are parts that are smooth and parts nodular encompassing the range of variation in nodularity one might encounter in clinical practice.

Experts

Through palpation alone, all five experts located all six lesions presented in the TL breast simulator. Time taken varied from 7 to 9 minutes. They agreed that the lesions felt like those they would come across in clinical practice and referred all lesions for follow-up. One of the experts said that object 4 (cyst (E,1)) did not need a mammogram follow-up. However, apart from this single difference, all other experts agreed about the follow-up for all lesions.

Interestingly, the experts also correctly identified and discriminated the normal nodularity (location (C,1), (C,2), (D,1), (D,2) in Figure 1), but all of them failed to note it on the answer sheet, despite being instructed to note all "masses." When asked afterward, they said that they had felt the "thickening" or "change of texture" but considered it normal so it had passed over it. Similarly, no expert noted simulated ribs or intercostal muscle as lesions.

The language used by the five experts to describe the feel of the lesions in the TL included the following:

- characteristics: "hard," "firm," "smooth," and "rubbery,"
- shape: "irregular" for the cancers and "regular" for the shallower cysts, and the deeper lesions were described as "unsure of shape"
- size: "large" for the cysts
- location: "deep" and the grid location coordinates specific to this test.

The double lesion (E,1) was correctly identified but the triple lesion was not (E-F,5). The language used to describe the lesions became less precise because their location became deeper (so rather than using a measurement like 2-cm diameter the description became "large"), although they were still correctly identified as "suspicious."

One of the experts commented that they had to press "too hard" and their hand got tired during the exercise and they had to swap hands, especially at the deeper end.

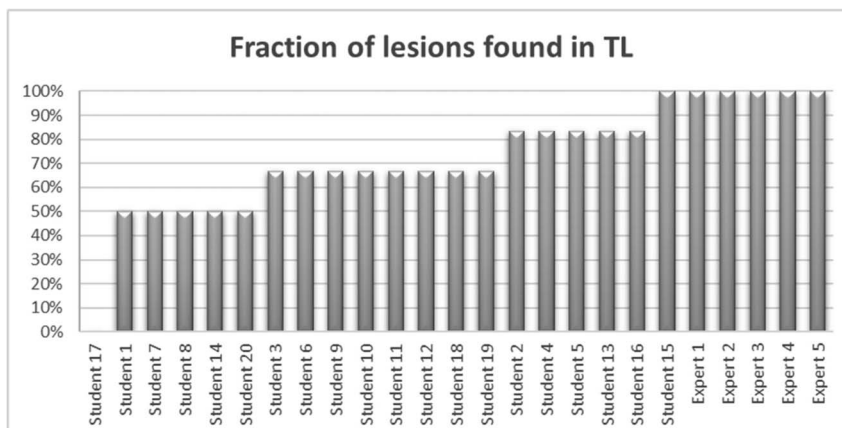


FIGURE 2. Student scores on left vs. expert scores on right, showing the percentage of lesions correctly identified in the TL (true positives).

Students

Only one student was able to locate all the lesions, one student was not able to identify any lesion, and the rest was identified between 50% and 80% (Fig. 2) with the mean of correctly identified true positives being 65% (Table 2). In addition, the one student who did not identify any lesions also misidentified the ribs as lesions, which gave a result of 10 false positives (ghosts) (Table 3). Fifteen percent of students noted the normal nodularity, although of these, 5% incorrectly said that it should be referred to a specialist as potentially abnormal.

The 95% confidence interval for the students' scores for detection of true positives of between 44% and 86% confirms that the students perform significantly worse than the experts who scored 100% (Table 2).

Object identification varied in difficulty (Table 4). Thus, 90% percent of students correctly identified object 1 as a lesion (A-cup depth), but only 15% correctly identified object 5, which, although it was structurally the same object as object 1, it was embedded much deeper (E-cup depth) and nearer to an area of normal nodularity.

The nurses evaluated the students who were examining the TL. None of the students in any of the questions received a rating of zero. All students were ranked as 2 or higher for examining all areas of the TL. Ninety percent of students were ranked 2 or higher for using appropriate hand position, only 5% having a low score. Only 30% of students always used appropriate pressure, whereas 90% were ranked 2 and higher (Table 5). The major comments by examiners were “methodical” or “haphazard”; “did the examination with pen in hand”; “long nails”; “used fingertips”; “very strong”; “inappropriate pressure”; “too deep”; “too gentle”; “good examination”; and “appropriate”. All the students passed under this method of assessment.

DISCUSSION

In this beginner student cohort, 95% of the students missed at least one lesion with the majority missing two to three lesions; thus, the teaching they had received was insufficient for them to be considered proficient in IDBM. Proficiency here is defined as generated zero false positives and false negatives in the TL, which all experts tested here achieved.⁵ The breast surgeons conducting the training felt that 30 minutes was insufficient time for adequate training although that is the standard time slot they are allocated to teach CBE. If we ignore the one student who did as well as the breast surgeons as an outlier, the results support this hypothesis and indicate that the present training was insufficient for students to acquire proficiency in breast lump detection. The individual variation in this student cohort in tactile skills and subsequent comprehension of the feel of normal versus abnormal structures in the breast highlighted

TABLE 2. Percentage of Lesions Detected Correctly by the Students: Mean, Standard Deviation, and 95% Confidence Interval

Statistic	Result, %
Mean	65
Standard error of the mean (SE _x)	10.66
95% confidence interval, 1.960SE _x	44.1–85.9
n	20

TABLE 3. Percentage of False Positives Reported

No. False Positives	Percentage of Students	Percentage of Experts
0	75	100
1	20	0
10	5	0

False positives are sometimes referred to as “ghosts.”

by this TL test suggests that some methods for testing these skills (IDBM) are needed.

The TL test results allow calculation of false positives and false negatives, both of which have very different implications. False negatives are a major worry in a clinical setting, because these might involve a physician-delayed diagnosis for breast cancer, especially in the setting of a normal mammogram, because some physicians do not know that mammography can miss 10% to 15% of palpable cancers.^{3–5} False positives in a clinical setting might produce unnecessary referrals, creating anxiety for the patient and increased workload for the specialists. The lack of comprehension of which breast lump was normal and abnormal indicates assessment of CBE tactility skills is needed.

The varying depth of objects in the TL allows the student to experience lesions in varying adiposity, because they are in real life, which will help test skills in IDBM in patients with, for example, very large or dense breasts. The TL showed that although 95% of students missed at least one lesion, they missed different ones for different reasons. The objects varied in difficulty in their identification by palpation mainly because of the depth but one object, object 5 (E,3) and (E,4), was deep and near an area of nonpathological normal nodularity that confused the students. Understanding which object each student missed and why can help inform remediation. This indicates that this TL can determine not only which students may need remediation but also where they may need it.

Examiner comments focused on the appropriate coverage, hand technique, and pressure applied. Corrections noted incapacity due to pen in hand and fingernails too long and included many pressure comments, the students either pressing too firmly or too gently. These are valuable observations, but if these were the only criteria against which the students were judged, they would be insufficient to determine whether the student could accurately find and correctly identify a breast mass. In addition, all students passed under this assessment criteria, often being given “benefit of the doubt” despite a wide variation in performance for IDBM skill. This method of assessment then cannot distinguish an actual IDBM skill from going through the correct motions of the procedure.

TABLE 4. Breakdown of the Percentage of Students Who Correctly Identified Each Individual Object

Object Number	Type of Lesion	Percentage of Students Correctly Identifying the Lesion
Object 1 (A–B,1–2)	Cancer	90
Object 2 (B,4–5)	Cyst	80
Object 3 (C,4–5)	Cancer	60
Object 4 (E,1)	Two cysts	20
Object 5 (E,3–4)	Cancer	15
Object 6 (F,4–5)	Three cysts	65

TABLE 5. Expert Rating (Proctored Result) of the Students by Visual Assessment

Rating	Did student examine all areas of the tray?	Did student use appropriate hand position?	Did student use appropriate pressure?
5 – always	70%	45%	30%
4	20%	20%	30%
3 – mostly	5%	15%	20%
2 – mostly	5%	10%	10%
1	0%	5%	10%
0 – not at all	0%	0%	0%
Blank	0%	5%	0%

The TL can be used after training in CBE to test tactile identification and the correct discrimination of different concealed breast masses, which is the goal of CBE. This provides, for the first time, a standardized effective and efficient method to test students' tactile sensing and comprehension ability to both identify and correctly discriminate between various types of breast masses (normal vs. abnormal) by touch alone.

This testing tool could facilitate a path for basic accreditation in CBE, in the same way that other important skills such as cardiopulmonary resuscitation are accredited, and provide a continuing personal development for general practitioners, who act as a gateway for breast specialists when it comes to screening for and diagnosing of breast disease.

CONCLUSIONS

Proctoring resulted in all students passing, which indicates that this method of assessing does not test specifically for IDBM skills. A separate test developed specifically to test IDBM is needed.

The TL breast simulator has had a preliminary validation by experts with all experts who examined it correctly locating all the lesions. Results from a previous validation study¹² indicate that it does mimic the tactility of (1) 60% of women's breasts in nodularity, (2) 53% for durability, and (3) anecdotally the most common lesions that could be encountered in clinical practice. It could thus have a useful role in adding the capacity to test students for the skill of identification and discrimination of different breast masses (IDBM) including testing for true positives, false positives, and false negatives. These detailed results might inform the type of remediation required for each testee. This capacity adds a missing capability to the mix of assessment instruments already used, thus potentially improving CBE training and assessment.

The TL seems to be a useful tool for assessing IDBM CBE. It could also be useful indirectly for teaching CBE in that if the testing were extended to include the middle of novice to expert, this would allow more precise mapping of the learning curve for this procedure, which could inform teaching styles, interventions, and student remediation, helping educators become more efficient and effective.

LESSON LEARNED

We should have specified to note only abnormal masses in the assessment instructions because the experts did this implicitly and the students needed explicit instructions to do this. The teaching time for CBE needs to be longer than

30 minutes. Lastly, description of the rating scales used needs to be clearly defined.

LIMITATIONS AND FUTURE DIRECTIONS

The study was limited by several factors. First, the number of students (N = 20) tested were small and the test was only done in one location and one time. It is recommended that this be repeated with additional students and multiple locations.

Second, these were novice students new to clinical settings and we did not control the teaching but allowed the breast surgeons to conduct their usual training. It is recommended that this testing be extended to include the middle of novice to expert continuum to allow more precise mapping of the learning curve for this procedure. Further testing might even reveal where in the progression proficiency is achieved.

In the future, this prototype would need to be brought to manufacturing readiness including, as with any product development, good quality control, and durability testing, as well as a variety of different TLs for repeated testing to show student improvement. The utility of the TL will depend on the ease of manufacture, which in part will be determined by economies of scale.

REFERENCES

1. Chalabian J, Dunnington G. Do our current assessments assure competency in clinical breast evaluation skills? *Am J Surg* 1998;175(6):497–502, 501.
2. World Cancer Research Fund. Worldwide data: World Cancer Research Fund. Available at: <http://www.wcrf.org/int/cancer-facts-figures/worldwide-data>. Accessed January 30, 2016.
3. Irwig L, Macaskill P, Houssami N. Evidence relevant to the investigation of breast symptoms: the triple test. *The Breast* 2002;11:215–220.
4. Haakinson DJ, Stucky CC, Dueck AC, Gray RJ, Wasif N, Apsey HA, et al. A significant number of women present with palpable breast cancer even with a normal mammogram within 1 year. *Am J Surg* 2010;200(6):712–718.
5. Goodson WH. Clinical breast examination and breast self-examination. In: Sauter ER, Daly MB, editors. *Breast Cancer Risk Reduction and Early Detection*. Berlin/Heidelberg, Germany: Springer Science+Business, LLC; 2010.
6. Day N. The need for performance and standardization of the best clinical breast exam. *J Nurse Pract* 2008;4(5):342–349.
7. Campbell H, McBean M, Mandin H, Bryant H. Teaching medical students how to perform a clinical breast examination. *Acad Med* 1994;69(12):993–995.
8. Saslow D, Hannan J, Osuch J, Alciati M, Baines C, Barton M, et al. Clinical breast examination: practical recommendations for optimizing performance and reporting. *CA Cancer J Clin* 2004;54:327–344.
9. Laufer S, Ray RD, D'Angelo ALD, Jones GF, Pugh CM. Use of simulators to explore specialty recommendation for a palpable breast mass. *Am J Surg* 2015;210(4):618–623.
10. Dilaveri C, Szostek J, Wang A, Cook D. Simulation training for breast and pelvic physical examination: a systematic review and meta-analysis. *BJOG* 2013;120:1171–1182.
11. Naylor RA, Hollett LA, Valentine RJ, Mitchell IC, Bowling MW, Ma AM, et al. Can medical students achieve skills proficiency through simulation training? *Am J Surg* 2009;198:277–282.
12. Veitch D, Bochner M, Fellner L, Leigh C, Owen H. Design, development and validation of more realistic models for teaching breast examination. *Design for Health* 2018;2(1):40–57.
13. Reece GP, Merchant F, Andon J, Khatam H, Ravi-Chandar K, Weston J, et al. 3D surface imaging of the human female torso in upright to supine positions. *Med Eng Phys* 2015;37(4):375–383.