

Accurate measurements of the skin surface area of the healthy auricle and skin deficiency in microtia patients

Otto, I.A.; van Doremalen, R.F.M.; Melchels, F.P.W.; Kolodzynski, M.N.; Pouran, Behdad; Malda, Jos; Kon, M.; Breugem, C.A.

Publication date

2016

Document Version

Final published version

Published in

Plastic and Reconstructive Surgery Global Open

Citation (APA)

Otto, I. A., van Doremalen, R. F. M., Melchels, F. P. W., Kolodzynski, M. N., Pouran, B., Malda, J., Kon, M., & Breugem, C. A. (2016). Accurate measurements of the skin surface area of the healthy auricle and skin deficiency in microtia patients. *Plastic and Reconstructive Surgery Global Open*, 4(12).

Important note

To cite this publication, please use the final published version (if applicable).
Please check the document version above.

Copyright

Other than for strictly personal use, it is not permitted to download, forward or distribute the text or part of it, without the consent of the author(s) and/or copyright holder(s), unless the work is under an open content license such as Creative Commons.

Takedown policy

Please contact us and provide details if you believe this document breaches copyrights.
We will remove access to the work immediately and investigate your claim.

Accurate Measurements of the Skin Surface Area of the Healthy Auricle and Skin Deficiency in Microtia Patients

Iris A Otto, MD, MSc*†

Rob F. M. van Doremalen, MSc†

Ferry P. W. Melchels, PhD†

Michail N. Kolodzynski, MD*

Behdad Pouran, MSc†‡

Jos Malda, PhD†§

Moshe Kon, MD, PhD*

Corstiaan C. Breugem, MD, PhD*¶

Background: The limited cranial skin covering auricular implants is an important yet underrated factor in auricular reconstruction for both reconstruction surgery and tissue engineering strategies. We report exact measurements on skin deficiency in microtia patients and propose an accessible preoperative method for these measurements.

Methods: Plaster ear models (n = 11; male:female = 2:1) of lobular-type microtia patients admitted to the University Medical Center Utrecht in The Netherlands were scanned using a micro-computed tomographic scanner or a cone-beam computed tomographic scanner. The resulting images were converted into mesh models from which the surface area could be calculated.

Results: The mean total skin area of an adult-size healthy ear was 47.3 cm², with 49.0 cm² in men and 44.3 cm² in women. Microtia ears averaged 14.5 cm², with 15.6 cm² in men and 12.6 cm² in women. The amount of skin deficiency was 25.4 cm², with 26.7 cm² in men and 23.1 cm² in women.

Conclusions: This study proposes a novel method to provide quantitative data on the skin surface area of the healthy adult auricle and the amount of skin deficiency in microtia patients. We demonstrate that the microtia ear has less than 50% of skin available compared with healthy ears. Limited skin availability in microtia patients can lead to healing problems after auricular reconstruction and poses a significant challenge in the development of tissue-engineered cartilage implants. The results of this study could be used to evaluate outcomes and investigate new techniques with regard to tissue-engineered auricular constructs. (*Plast Reconstr Surg Glob Open* 2016;4:e1146; doi: 10.1097/GOX.0000000000001146; Published online 22 December 2016.)

Microtia is a congenital malformation of the external ear, characterized by underdevelopment of the auricle, ranging from a slight reduction in

size to a peanut-like lobular structure or its complete absence.¹⁻³ The prevalence of microtia depends on ethnicity and region, with an overall prevalence of 1.55 per 10,000 births (confidence interval, 1.50-1.60) and with lobular-type microtia being the most frequent type.¹ Associated craniofacial abnormalities include auditory canal atresia, middle ear dysplasia, mandibular hypoplasia, facial cleft, or facial asymmetry.^{2,4}

There are various options for the treatment of microtia, including osseointegrated prostheses and alloplastic implants such as Medpor.⁵⁻⁹ Currently, surgical reconstruction of the auricle using autologous costal cartilage is most often performed.¹⁰⁻¹⁴ The carved framework is in fact considerably thicker and less pliable than natural cartilage to maintain the shape and detail of the implant when covered with the thick cranial skin. The skin poses some important but often overlooked challenges in auric-

From the Departments of *Plastic, Reconstructive and Hand Surgery and †Orthopaedics, University Medical Center Utrecht, Utrecht, The Netherlands; ‡Department of Biomechanical Engineering, Faculty of Mechanical, Maritime, and Materials Engineering, Delft University of Technology (TU Delft), Delft, The Netherlands; §Department of Equine Sciences, Faculty of Veterinary Medicine, Utrecht University, Utrecht, The Netherlands; and ¶Department of Plastic Surgery, Meander Medical Centre, Amersfoort, The Netherlands.

Received for publication October 6, 2016; accepted October 6, 2016.

Current address for Dr. Melchels: Institute of Biological Chemistry, Biophysics and Bioengineering, Heriot-Watt University, Edinburgh, Scotland, EH14 4AS.

Presented at 11th European Craniofacial Congress, June 25, 2015, Gothenburg, Sweden.

Copyright © 2016 The Authors. Published by Wolters Kluwer Health, Inc. on behalf of The American Society of Plastic Surgeons. All rights reserved. This is an open-access article distributed under the terms of the Creative Commons Attribution-Non Commercial-No Derivatives License 4.0 (CCBY-NC-ND), where it is permissible to download and share the work provided it is properly cited. The work cannot be changed in any way or used commercially without permission from the journal.

DOI: 10.1097/GOX.0000000000001146

Disclosure: I.A. Otto was supported by the Netherlands Organization for Scientific Research (Fellowship in Regenerative Medicine). F.P.W. Melchels was supported by a Marie Curie grant from the European Commission (PIOF-GA-272286). B. Pouran and Dr. Malda were supported by the Dutch Arthritis Foundation. None of the other authors has any financial disclosures. The Article Processing Charge was paid for by the authors.

ular reconstruction, including limited skin availability and contractive forces on the implant.^{14–16}

The skin is a highly viscoelastic tissue and therefore has high mechanical restraining capabilities.^{17,18} Elastin and collagen are among the structural components ensuring tensile strength and extensibility. With increasing strain, the skin offers more resistance and presses the underlying material. These contraction forces may lead to healing problems after auricular reconstruction.^{15,16} This is especially evident in microtia patients, who may have only limited skin available.⁸

The same problem arises in regenerative approaches for engineering an auricular implant. Although many advances have been achieved in ear-shaped cartilage regeneration, a major challenge is the maintenance of the size and shape of the relatively large complex-shaped 3-dimensional (3D) construct after implantation. The covering skin applies a great deal of pressure on the neocartilage implant, which initially lacks adequate mechanical stability to withstand such forces. With less skin available, these forces will increasingly hamper the development of the auricular construct.¹²

To generate sufficient skin coverage of the implanted framework in auricular reconstruction, tissue expansion, flap transposition, and skin grafts can be utilized.^{14,19,20} There is very limited information in the literature on the actual amount of skin in the normal ear. Yazar et al²¹ calculated the area of skin covering the healthy human auricle in a Turkish population. More relevantly, no data are available on the skin surface area of microtia ears, leaving the shortage of skin that must be compensated for with, for example, skin grafting, an educated guess.

This retrospective study addresses these issues and provides quantitative data on the skin surface area of both healthy and microtia ears in humans, with specific interest in the amount of missing skin for adequate coverage of an auricular implant. In addition, we present an accessible method to assess skin requirements preoperatively in patients with auricular deformations. Moreover, this method may be especially interesting as an evaluation tool for size evaluation after reconstruction or analysis of a tissue-engineered auricular implant.

METHODS

Patient Demographics

Plaster ear models of microtia patients admitted to the University Medical Center Utrecht, The Netherlands, have been collected between 1999 and 2005. Microtia ears of the lobular type were selected for this study and compared with their contralateral normal counterparts. The lower age limit of 9 years was chosen based on the age at which the majority of auricular reconstructions are performed,¹¹ coinciding with the average age of maturity of the ear.^{22,23} All procedures performed in the study involving human participants were in accordance with the ethical standards of the institutional research committee and with the 1964 Helsinki Declaration and its later amendments or comparable ethical standards. Because of anonymous plaster model analysis, the institutional review committee required no ethical approval or informed consent.

CT Scanning

Plaster models were scanned using a micro-computed tomographic (CT) scanner (Quantum FX, PerkinElmer [PerkinElmer, Waltham, Mass.]; tube voltage, 90 kV; tube current, 180 μ A; scan time, 17 seconds; voxel size, $0.146 \times 0.146 \times 0.146 \text{ mm}^3$) or a cone-beam CT scanner (Next Generation, i-Cat [i-Cat, Hatfield, Pa.]; voxel size, of $0.250 \times 0.250 \times 0.250 \text{ mm}^3$) depending on the size of the models. The cone-beam CT scanner yielded Digital Imaging and Communication in Medicine images (DICOM). The images from the micro-CT scanner were converted into DICOM files as well using Analyze 11.0 (MayoClinic, Rochester, Minn.).

Creation of 3D Models

Volumetric data of the plaster models were extracted from the scans with Matlab R2013a (The Mathworks Inc., Natick, Mass.) using a threshold technique, which defines the volumetric data as every pixel above a certain threshold value. The isosurface, that is, the 3D surface that represents the points of the constant value, was subsequently computed from the volumetric data and exported into stereolithography (STL) files, known as mesh models. A mesh model is a representation of the surface of the original plaster model. They are made up of small connecting triangles (faces), defined by coordinates in a 3D grid (vertices). Each face has its own surface area, and the accumulated areas of all faces will provide an accurate measurement of the surface area of the plaster model (Fig. 1).

Surface Area Calculation

The surface area calculation was subsequently performed using MeshLab (Visual Computing Lab, Pisa, Italy), which is a 3D mesh processing system. By computing the geometric measures, a surface in square millimeters (mm^2) was obtained. The calculation for the auricular

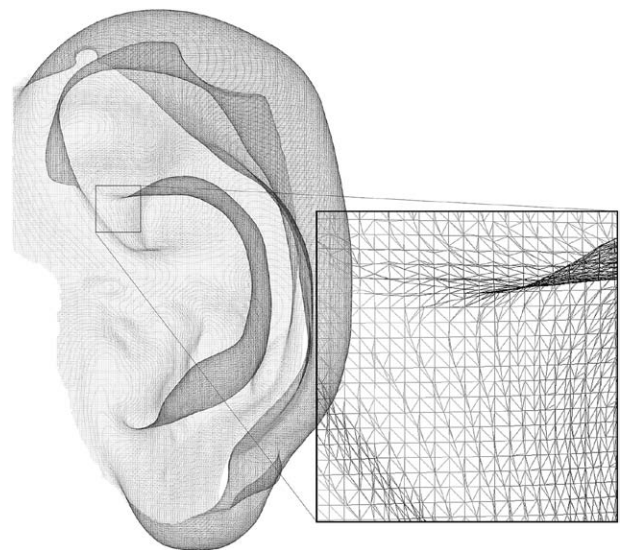


Fig. 1. Mesh model based on CT scan. The surface of the original model is represented by small connecting triangles (faces), which all have their own surface areas. Accumulation of these areas provides an accurate measurement of the total surface area of the model.

surface area itself differs from the calculation of the skin deficiency, as these require different area boundaries of the models.

Determination of the Auricular Surface Area

The first objective of this study is to determine the exact auricular surface area. Therefore, the boundaries of the area included in the calculations were set at the curvature where the auricle joins the cranium. The external ear, including the lobe, was subsequently cut out at its base by means of a drawing tool (Fig. 2). This approach will be referred to as the “base method” throughout this article.

Determination of the Amount of Skin Deficiency in Microtia Ears

The second objective is to determine the amount of skin deficiency for auricular reconstruction in microtia patients. The difference between the surface area of the healthy ear and the microtia ear equals the amount of skin missing to cover an implant with the same surface as the healthy contralateral ear. However, because of the differences in shape, there is a discrepancy in base areas of the healthy ear and the microtia ear. Therefore, a fixed domain around both ears was selected (Fig. 3) to eliminate such confounding factors. Comparison of identical domains will allow objective calculation of the difference in skin surface areas and thus the determination of the amount of skin deficiency. This approach will be referred to as the “fixed method.”

Data Analysis

Calculations of the mean and SD of the surface area were performed using Microsoft Excel (Microsoft Corporation,

Washington, D.C.). To evaluate the validity of our method, the results were compared with the only comparable study.²¹ Different significance in comparison to this previous study was calculated using a Welch *t* test with GraphPad (GraphPad Software, La Jolla, Calif.). Different significance between women and men was calculated using the Mann–Whitney *U* test with SPSS (IBM, New York, N.Y.). A significant difference was defined as *P* value less than 0.05.

RESULTS

Patient Demographics

Eleven patients with lobular-type microtia were included in this retrospective study (male:female = 2:1). Patients were between 9 and 52 years old at the time of the first reconstruction surgery, with an average of 26 years and a mean of 22 years (male: average, 27 years, mean, 22 years; female: average, 24 years, mean, 20 years).

Surface Area of the Auricle

The exact auricular surface area of a healthy adult-size human ear, as determined using the base method, was calculated to be 47.3 cm² (SD, 4.4) overall, where men generally had larger ears (49.0 cm²; SD, 4.7) than women (44.2 cm²; SD, 1.6; *P* = 0.073; Table 1). Using the same method, microtia ears average 14.5 cm² (SD, 4.0), with 15.6 cm² (SD, 4.7) in men and 12.6 cm² (SD, 1.9) in women (*P* = 0.412; Table 1).

Amount of Skin Deficiency in Microtia Ears

The difference between the surface area of the healthy ear and the microtia ear, as calculated using the fixed method, can be interpreted as the amount of skin missing to cover the auricular implant. The mean skin

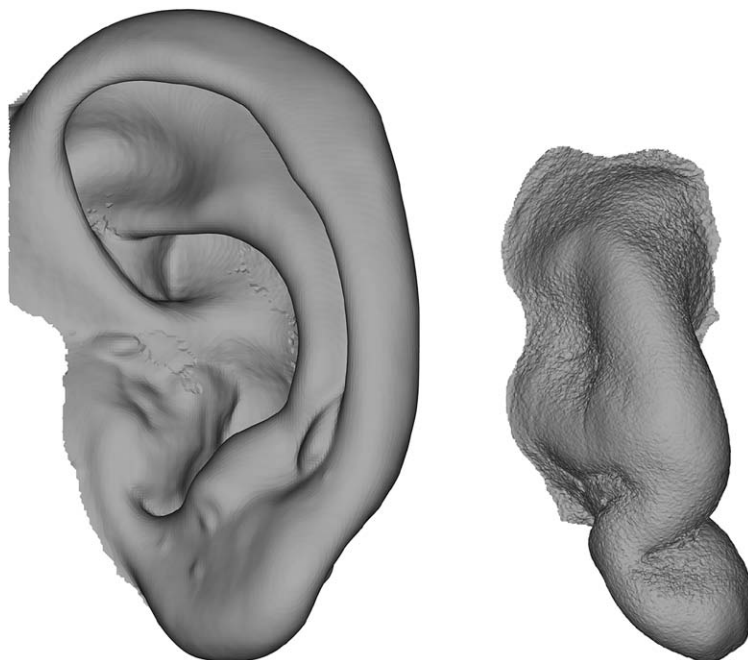


Fig. 2. “Base method.” Boundaries used in the base method, where the ear model is cut out at its base for calculation of the auricular surface area of the healthy adult ear.

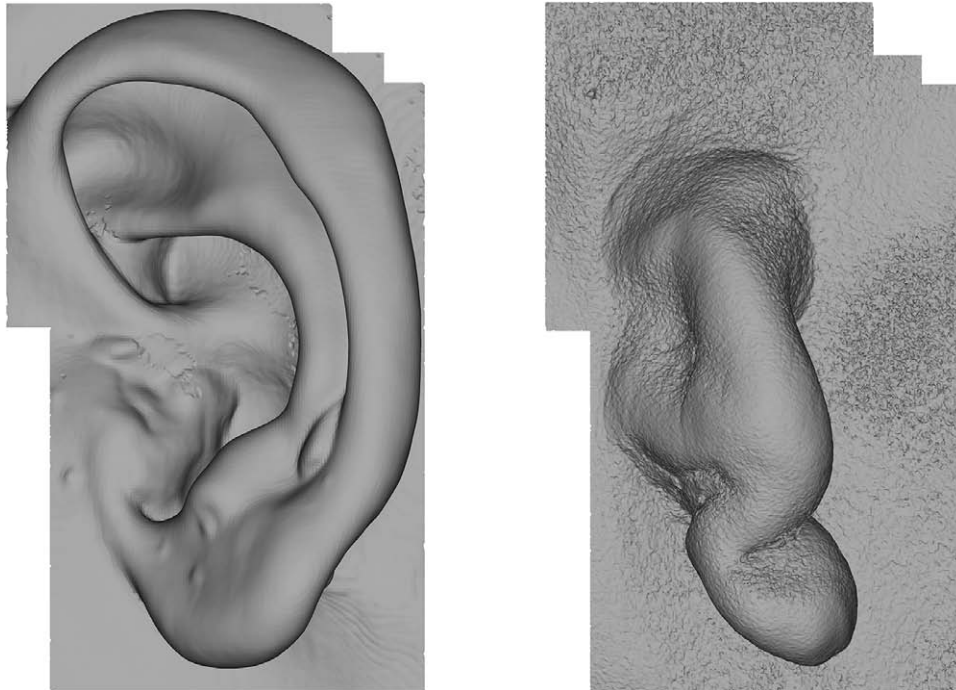


Fig. 3. “Fixed method.” Boundaries used in the fixed method, where a fixed domain around the respective ears enables quantification of skin deficiency.

deficiency was 25.4 cm² (SD, 4.6), with 26.7 cm² in men (SD, 4.6) and 23.1 cm² in women (SD, 4.1; *P* = 0.315; Table 2).

DISCUSSION

Limited skin availability in microtia patients proves to be a problem in both surgical and regenerative medicine approaches for the reconstruction of the auricle. Skin expansion and skin grafting solutions are currently used to generate sufficient skin coverage of the reconstructed implant, yet the actual amount of skin required for an implant to be adequately covered remains an educated guess. Meanwhile, novel tissue-engineering approaches to reconstruct the auricle are hampered in several ways.¹² One of the main problems is that the construct does not keep its shape under the tight skin envelope.¹⁶ Although we fully agree that mechanical properties of the tissue-engineered auricle should also be investigated,²⁴ it seems imperative to objectively assess the amount of skin deficiency in the microtia patient.

This retrospective study used 3D scan images to calculate the auricular surface area. The results indicate that

the healthy human adult-size auricle averages 47.3 cm² overall, with 49.0 cm² in men and 44.3 cm² in women in our patient population. These numbers are comparable with a similar study conducted by Yazar et al²¹ (2013). Their study involved a technique based on measuring cutout silicone impression models, conducted on a population of adult Turkish men and women. The skin area calculated using this technique was also determined with boundaries set at the curvature from the auricle to skull, and by adding the mean anterior and posterior surface areas, the data could be compared with the current study. The male population in the study by Yazar et al²¹ (2013) exhibited a total skin surface area of 51.4 cm² (*P* = 0.23), whereas woman had quite smaller ears with 41.0 cm² (*P* = 0.03), averaging 46.3 cm² overall (*P* = 0.51). Overall, the auricular surface areas in both studies do not differ significantly, as expected. The significant difference in the female Turkish population may be explained by the small subject group in our study or possibly an ethnical effect.²⁵

Calculating the exact auricular skin surface area and subsequently the amount of skin deficiency contributes to

Table 1. Mean Skin Surface Area of the Healthy and the Microtia Ears

	Healthy Ear (cm ²)	Microtia Ear (cm ²)
Male (n = 7)	49.0 (SD, 4.7)	15.6 (SD, 4.7)
Female (n = 4)	44.2 (SD, 1.6)	12.6 (SD, 1.9)
Overall (n = 11)	47.3 (SD, 4.4)	14.5 (SD, 4.1)

Using the base method, where the auricle was cut out at its base, the exact auricular surface area was determined.

Table 2. Mean Difference in the Skin Surface Area between Healthy and Microtia Ears, as Calculated Using the Fixed Method

	Difference (cm ²)	Deficiency (%)
Male (n = 7)	26.7 (SD, 4.6)	54.5
Female (n = 4)	23.1 (SD, 4.1)	52.3
Overall (n = 11)	25.4 (SD, 4.6)	53.1

By selecting a fixed domain around both ears, an objective calculation of the difference in surface area was obtained. This difference can be interpreted as the amount of skin deficiency on the microtia side compared with the healthy ear.

the general knowledge on the properties of the healthy adult auricle and may aid surgeons preoperatively. The method we propose here to calculate the auricular surface area yields similar results as a previous study.²¹ However, this base method is not appropriate for determining the amount of skin deficiency on the microtia side, as it does not take into account differences in the area where the auricle joins the skull, and there is a discrepancy in this base area between microtia and healthy ears. In addition, the determination of the base borders is rather subjective and even more challenging to define in an underdeveloped auricular structure. A more objective way to calculate the difference in skin area between the healthy and the microtia ear, as proposed in the current study, is by using a fixed border around both ears, which enables comparison between 2 identical domains. The subsequently calculated difference in the surface area can be interpreted as the amount of skin missing for adequate coverage of a reconstructed auricular implant. After this fixed method, our study indicates an average shortage of 25.4 cm² overall, with 26.7 cm² in men and 23.1 cm² in women. These numbers indicate a skin deficiency on the microtia side of more than 50%.

The mechanical properties of the skin enable it to offer more resistance with increasing strain.¹⁸ Stretching the skin over an auricular implant places increasing forces on the underlying material. The findings of this study indicate that there is a significant deficiency of skin on the microtia side, making the influence of the mechanical properties of the skin on the auricular implant, a factor that should not be ignored in clinical practice. In regenerative medicine approaches, the contractive forces of the skin play an especially important yet often overlooked role as well. Previous experiments are mostly performed in murine models with relatively loose skin,¹⁶ contrary to the thick and stiff human cranial skin.¹⁸ In microtia patients, where there is a loss of skin over the ear and mastoid area, the contractive forces will be even stronger. Tissue-engineered constructs may not be able to maintain their shape in the tight skin envelope in these patients. Providing extra skin through, for example, tissue expansion may be imperative to a successful tissue-engineered implant. This study could provide an impetus for further research on regenerative medicine approaches to microtia and auricular reconstruction.

We have presented a reliable and simple method for the calculation of skin deficiency in microtia patients, one that is less time consuming and labor intensive than the method proposed in a previous study.²¹ We believe that our method can easily be applied in clinical practice in preparation of auricular reconstruction or for evaluating postreconstruction aesthetic outcomes, yet it may be even more interesting as an evaluation tool for size preservation of large and complex-shaped tissue-engineered constructs.

Although in this study only lobular-type microtia patients were included, this method can potentially be applied to all types of auricular deformation. Scanning plaster models casted from the patient relieves the diagnostic burden on the patient and obviates radiation exposure. In the future, handheld 3D laser scanners may make

the process even easier.²⁶ The presence of small bubbles in the plaster and cotton wads in the ear canal are of little importance in the measurements, as these may only influence the results at the square millimeter level. One limitation of the current study is the use of 2 different types of CT scanners and the subjective determination of the boundaries of the base of the ear. Nevertheless, the difference in resolution between the 2 scanners is only marginal, and the potential fluctuations arising from the above factors are on a negligible square millimeter scope.

In conclusion, this retrospective study is one of the 2 studies looking at the area of skin covering the auricle. It determined the exact skin surface area of the healthy human auricle and proposed a new method by which accurate calculation of the skin deficit in microtia patients can be achieved. This method could aid reconstructive surgery in clinical practice. Our study demonstrates that microtia patients have a deficiency of more than 50% when compared with the healthy ear. Supplementing this amount of skin one way or another in microtia patients may improve healing after auricular reconstruction and diminish excessive forces within neocartilage development in engineered constructs. Future studies should be performed to evaluate the use of this method to analyze aesthetic results after ear reconstruction or the usage during clinical practice (e.g., to determine the size of the skin graft during the second stage of ear reconstruction).

Iris A. Otto, MD, MSc

Department of Plastic, Reconstructive and Hand Surgery
University Medical Center Utrecht
Heidelberglaan 100
3508 GA Utrecht
The Netherlands
E-mail: i.a.otto@umcutrecht.nl

ACKNOWLEDGMENT

We thank Jaron Roubos for his assistance in scanning the plaster models with the cone-beam computed tomographic scanner.

REFERENCES

1. Luquetti DV, Leoncini E, Mastroiaco P. Microtia-anotia: a global review of prevalence rates. *Birth Defects Res A Clin Mol Teratol.* 2011;91:813–822.
2. Heike CL, Hing AV, Aspinall CA, et al. Clinical care in craniofacial microsomia: a review of current management recommendations and opportunities to advance research. *Am J Med Genet C Semin Med Genet.* 2013;163C:271–282.
3. van Nunen DP, Kolodzynski MN, van den Boogaard MJ, et al. Microtia in the Netherlands: clinical characteristics and associated anomalies. *Int J Pediatr Otorhinolaryngol.* 2014;78:954–959.
4. Alasti F, Van Camp G. Genetics of microtia and associated syndromes. *J Med Genet.* 2009;46:361–369.
5. Reinisch JF, Lewin S. Ear reconstruction using a porous polyethylene framework and temporoparietal fascia flap. *Facial Plast Surg.* 2009;25:181–189.
6. Park C, Yoo YS, Hong ST. An update on auricular reconstruction: three major auricular malformations of microtia, prominent ear and cryptotia. *Curr Opin Otolaryngol Head Neck Surg.* 2010;18:544–549.

7. Nayyer L, Patel KH, Esmaili A, et al. Tissue engineering: revolution and challenge in auricular cartilage reconstruction. *Plast Reconstr Surg*. 2012;129:1123–1137.
8. Sivayoham E, Woolford TJ. Current opinion on auricular reconstruction. *Curr Opin Otolaryngol Head Neck Surg*. 2012;20:287–290.
9. Bichara DA, Pomerantseva I, Zhao X, et al. Successful creation of tissue-engineered autologous auricular cartilage in an immunocompetent large animal model. *Tissue Eng Part A*. 2014;20:303–312.
10. Ciorba A, Martini A. Tissue engineering and cartilage regeneration for auricular reconstruction. *Int J Pediatr Otorhinolaryngol*. 2006;70:1507–1515.
11. Breugem CC, Stewart KJ, Kon M. International trends in the treatment of microtia. *J Craniofac Surg*. 2011;22:1367–1369.
12. Bichara DA, O'Sullivan NA, Pomerantseva I, et al. The tissue-engineered auricle: past, present, and future. *Tissue Eng Part B Rev*. 2012;18:51–61.
13. Im DD, Paskhover B, Staffenberg DA, et al. Current management of microtia: a national survey. *Aesthetic Plast Surg*. 2013;37:402–408.
14. Liu J, Sun J, Li X. Total auricular reconstruction without skin grafting. *J Plast Reconstr Aesthet Surg*. 2011;64:1312–1317.
15. Bauer BS. Reconstruction of microtia. *Plast Reconstr Surg*. 2009;124(1 Suppl):14e–26e.
16. Zhou L, Pomerantseva I, Bassett EK, et al. Engineering ear constructs with a composite scaffold to maintain dimensions. *Tissue Eng Part A*. 2011;17:1573–1581.
17. Edwards C, Marks R. Evaluation of biomechanical properties of human skin. *Clin Dermatol*. 1995;13:375–380.
18. Hussain SH, Limthongkul B, Humphreys TR. The biomechanical properties of the skin. *Dermatol Surg*. 2013;39:193–203.
19. Zhang GL, Zhang JM, Liang WQ, et al. Implant double tissue expanders superposingly in mastoid region for total ear reconstruction without skin grafts. *Int J Pediatr Otorhinolaryngol*. 2012;76:1515–1519.
20. Kludt NA, Vu H. Auricular reconstruction with prolonged tissue expansion and porous polyethylene implants. *Ann Plast Surg*. 2014;72(Suppl 1):S14–S17.
21. Yazar M, Sevim KZ, Irmak F, et al. Predicting skin deficits through surface area measurements in ear reconstruction and adult ear surface area norms. *J Craniofac Surg*. 2013;24:1206–1209.
22. Farkas LG, Posnick JC, Hreczko TM. Anthropometric growth study of the ear. *Cleft Palate Craniofac J*. 1992;29:324–329.
23. Siegert R, Magritz R. Malformation and plastic surgery in childhood. *GMS Curr Top Otorhinolaryngol Head Neck Surg*. 2014;13:Doc01.
24. Nimeskern L, van Osch GJ, Müller R, et al. Quantitative evaluation of mechanical properties in tissue-engineered auricular cartilage. *Tissue Eng Part B Rev*. 2014;20:17–27.
25. Schuller FP. A comparative study of the temporal bone in three populations of man. *Am J Phys Anthropol*. 1976;44:453–468.
26. Chen J, Wu X, Wang Y, et al. 3D shape modeling using a self-developed hand-held 3D laser scanner and an efficient HT-ICP point cloud registration algorithm. *Opt Laser Technol*. 45:414–423.